THE REPRODUCTIVE SYSTEMS

- Overall function is to produce offspring
- Testes produce sperm and male sex hormones
- Ovaries produce eggs and female sex hormones
- Mammary glands produce milk

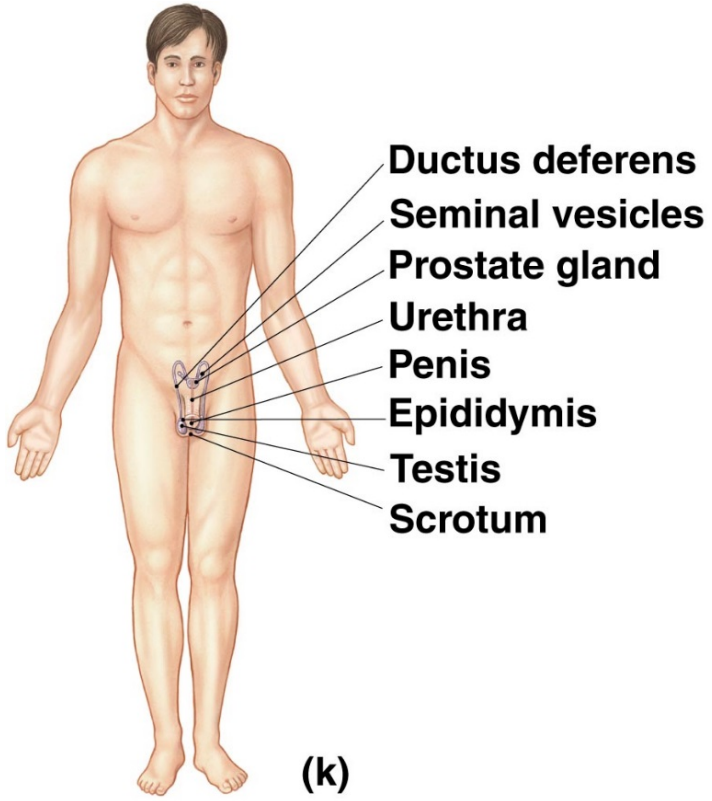

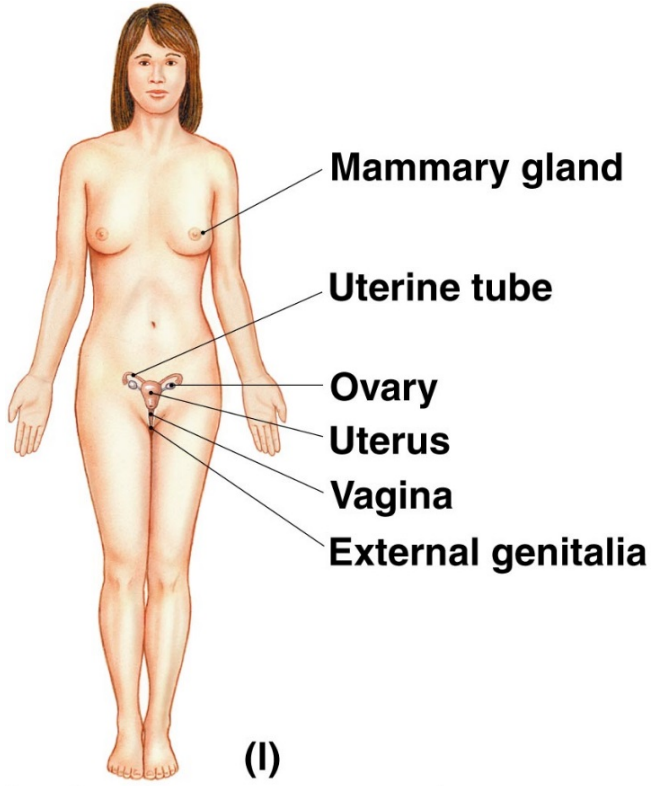

COMPILED BY HOWIE BAUM

INTRODUCTION

The reproductive system is a collection of internal and external organs — in both males and females — that work together for the purpose of procreating.

Due to its vital role in the survival of the species, many scientists feel that the reproductive system is among the most important systems in the entire body.

Of the body's major systems, the reproductive system is the one that differs most between sexes, and the only system that does not function until puberty.

The male reproductive system is responsible for delivering sperm to the female reproductive system

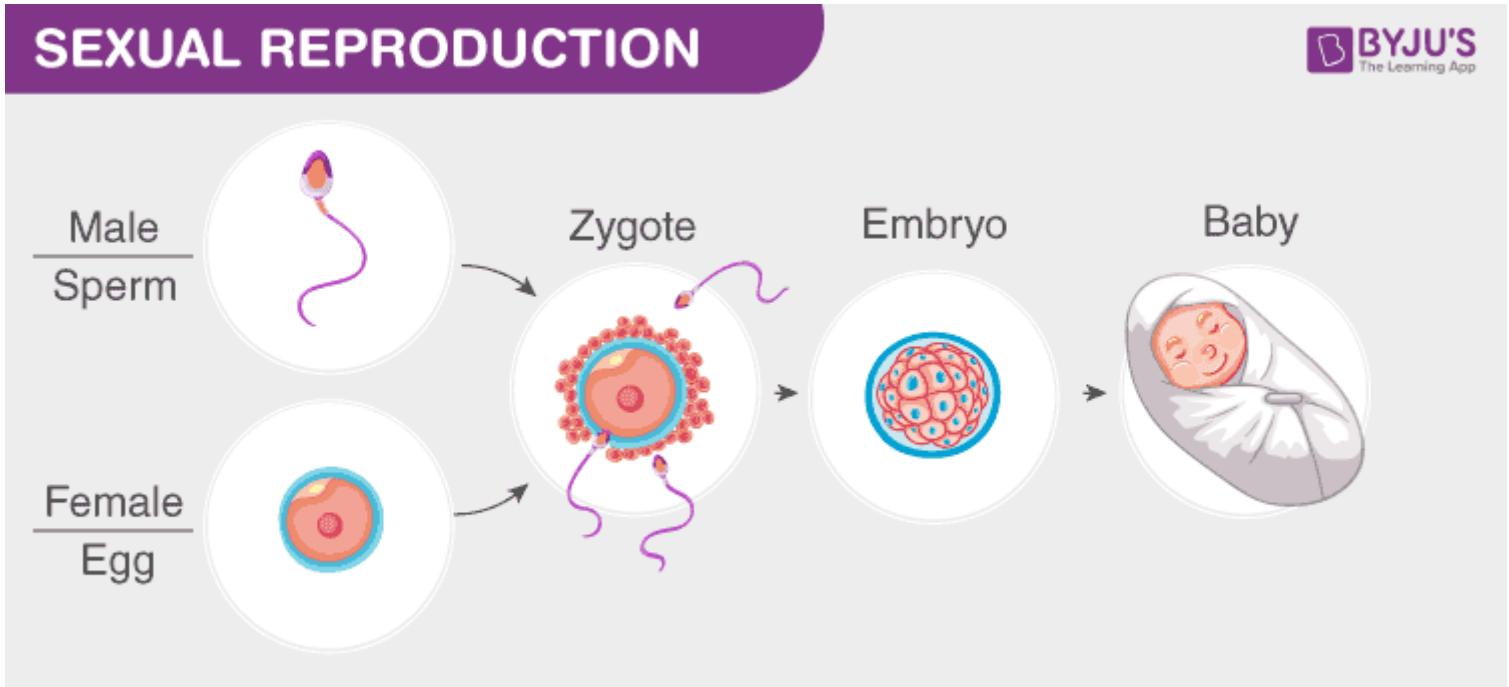

MALE REPRODUCTIVE SYSTEM

In males, the reproductive organs include the penis, the testes, a number of storage and transport ducts, and some supporting structures.

The two oval-shaped testes (also called testicles) lie outside the body in a pouch of skin called the scrotum, where they can maintain the optimum temperature for sperm production – approximately 5° F, lower than body temperature.

Testes are oval-shaped glands responsible for the manufacture of sperm and the sex hormone testosterone.

From each testis, sperm pass into a coiled tube – the epididymis – for the final stages of maturation.

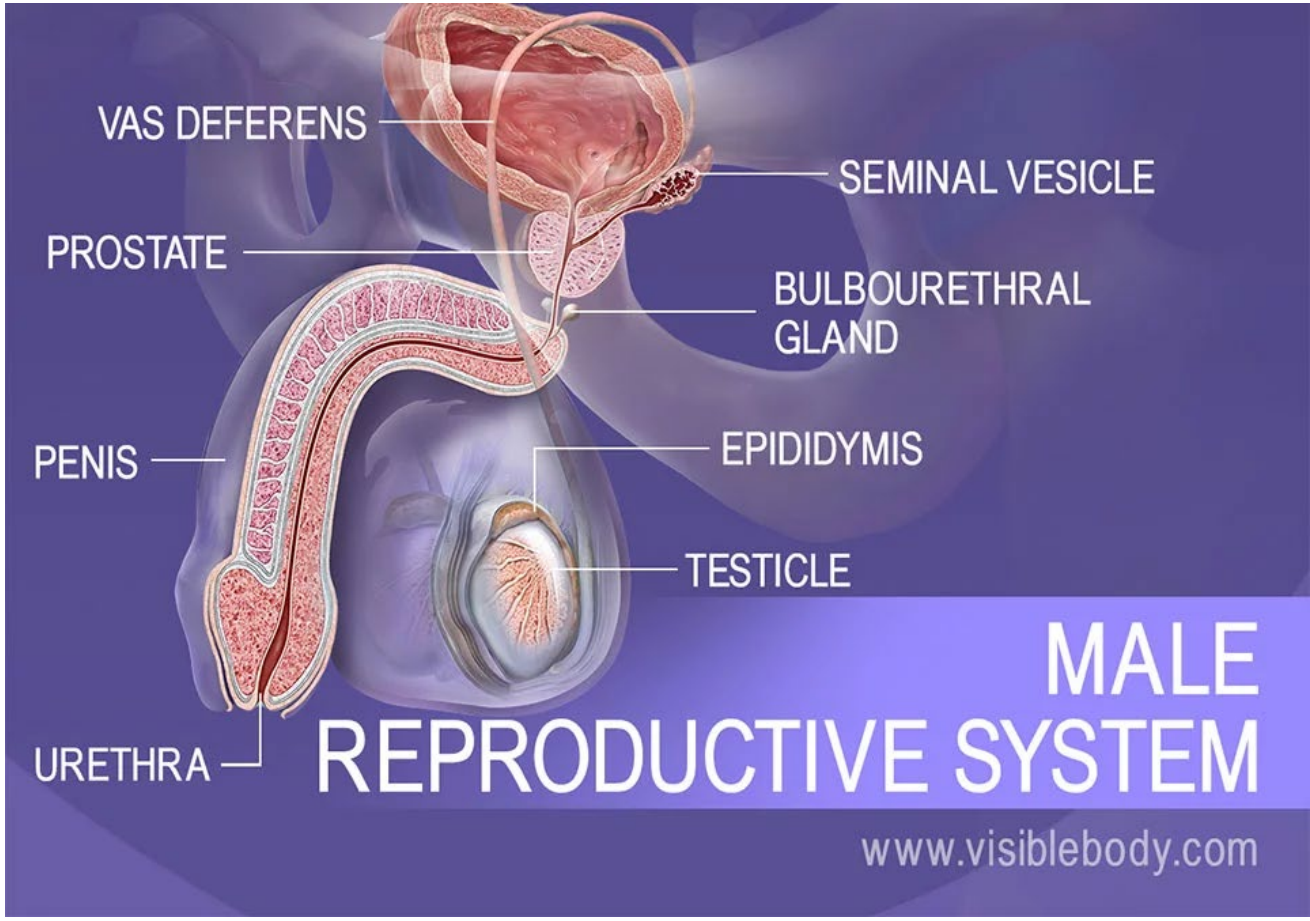

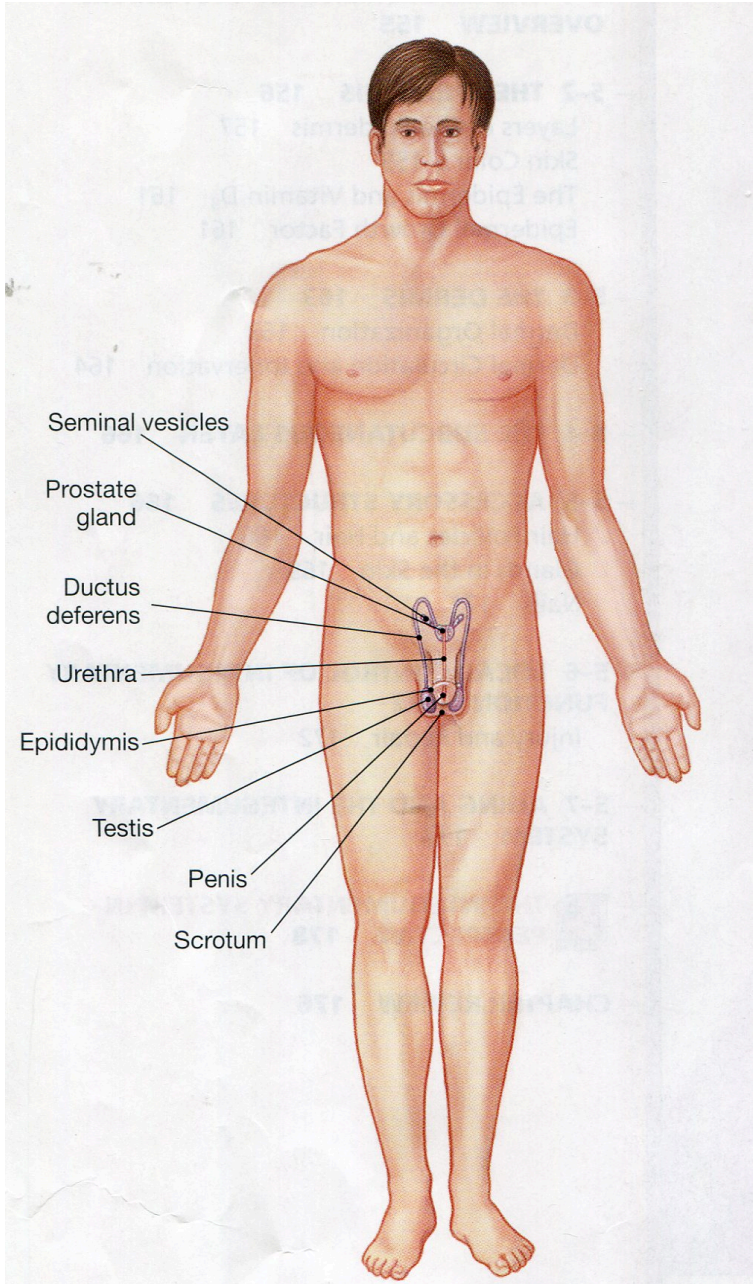

(k) THE MALE REPRODUCTIVE SYSTEM

Produces sex cells and hormones

Organ/Component	Primary Functions
Testes	Produce sperm and hormones (*see part e*)
Accessory Organs	
Epididymis	Acts as site of sperm maturation
Ductus Deferens (Sperm Duct)	Conducts sperm between epididymis and prostate gland
Seminal Vesicles	Secrete fluid that makes up much of the volume of semen
Prostate Gland	Secretes fluid and enzymes
Urethra	Conducts semen to exterior
External Genitalia	
Penis	Contains erectile tissue; deposits sperm in vagina of female; produces pleasurable sensations during sexual activities
Scrotum	Surrounds the testes and controls their temperature

INSIDE THE SCROTUM

The scrotum contains two testes (testicles) where sperm are manufactured within tubes called seminiferous tubules, and the two epididymides where sperm are stored.

Unlike female egg maturation, which occurs in cycles and ceases at menopause, sperm production is continuous, reducing gradually with age.

Each epididymis is a tube about 20 feet long, which is tightly coiled and bunched into a length of just 2 inches.

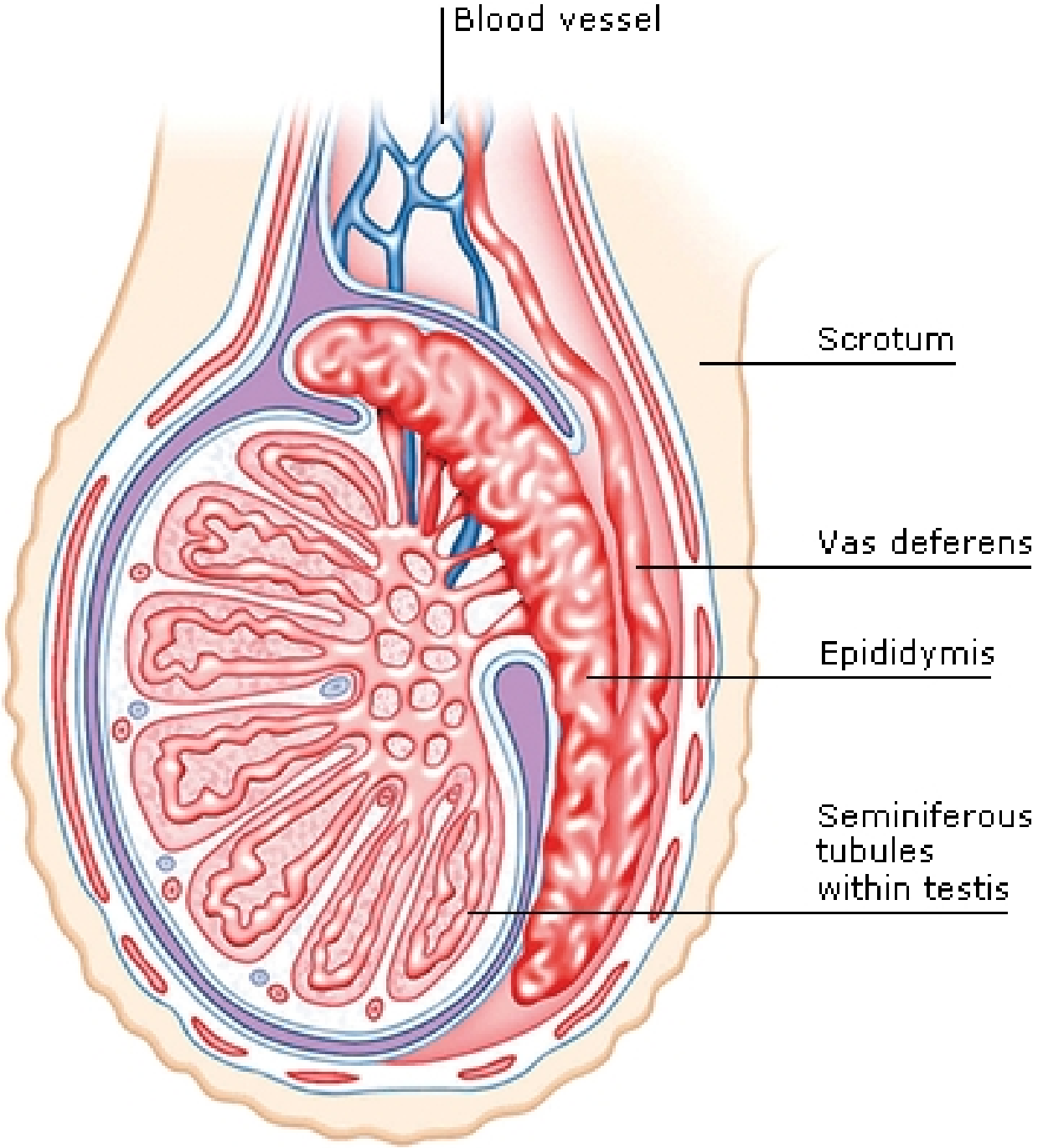

MAKING SPERM

Each testis is a mass of more than 800 tightly looped and folded vessels known as seminiferous tubules.

Inside each tubule, sperm begin as blob-like cells called **spermatogonia** lining the inner wall.

These pass through a larger stage, as **primary spermatocytes**, then become smaller as **secondary spermatocytes**, and **begin to develop tails as spermatids.**

As all of this happens, they move steadily towards the middle of the tubule.

The spermatids finally develop into ripe sperm with long tails.

Thousands of sperm are produced every second, each taking about two months to mature.

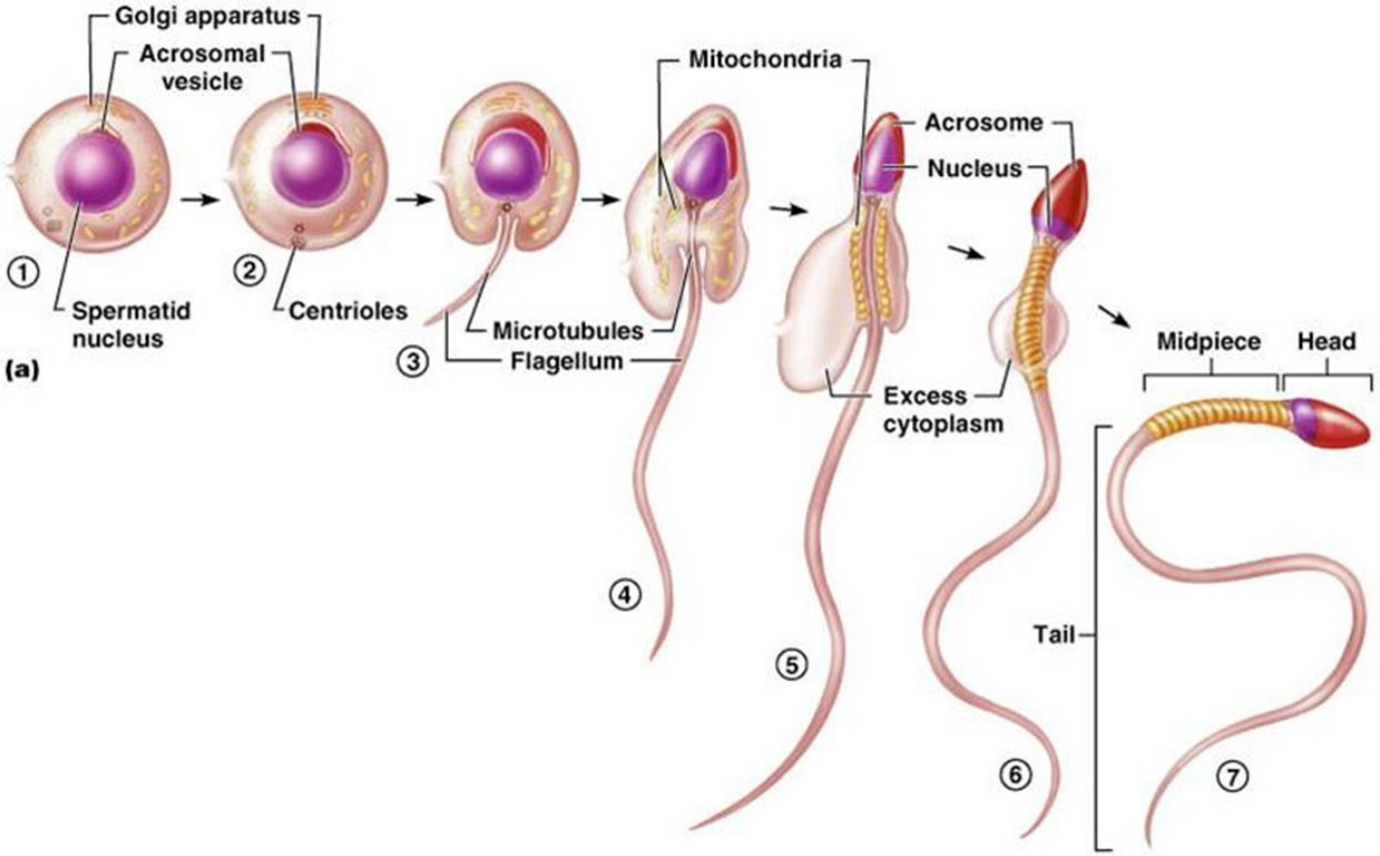

DIFFERENCE IN SEMEN AND SPERM

Semen, also known as seminal fluid, is much more than just sperm.

Sperm is only about 5 to 10% of any given male single ejaculation and the rest is fructose (aka sugar), fatty acids, and proteins to nourish the sperm during their journey.

Sperm Count

A man will produce roughly 525 billion sperm during his whole lifetime and close to 1 billion per month.

There are around 200 to 500 million sperm in an average in a single human ejaculation !!

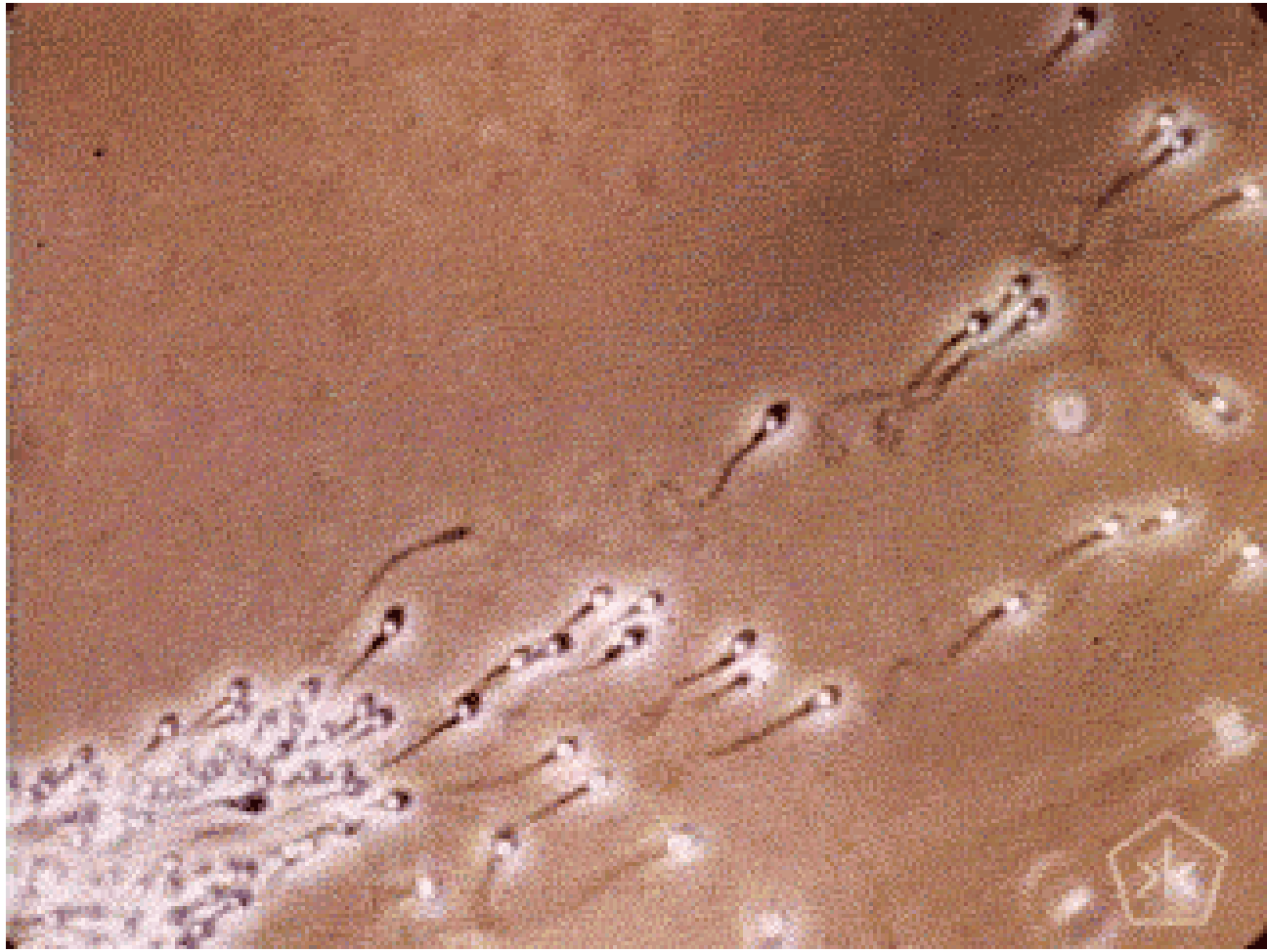

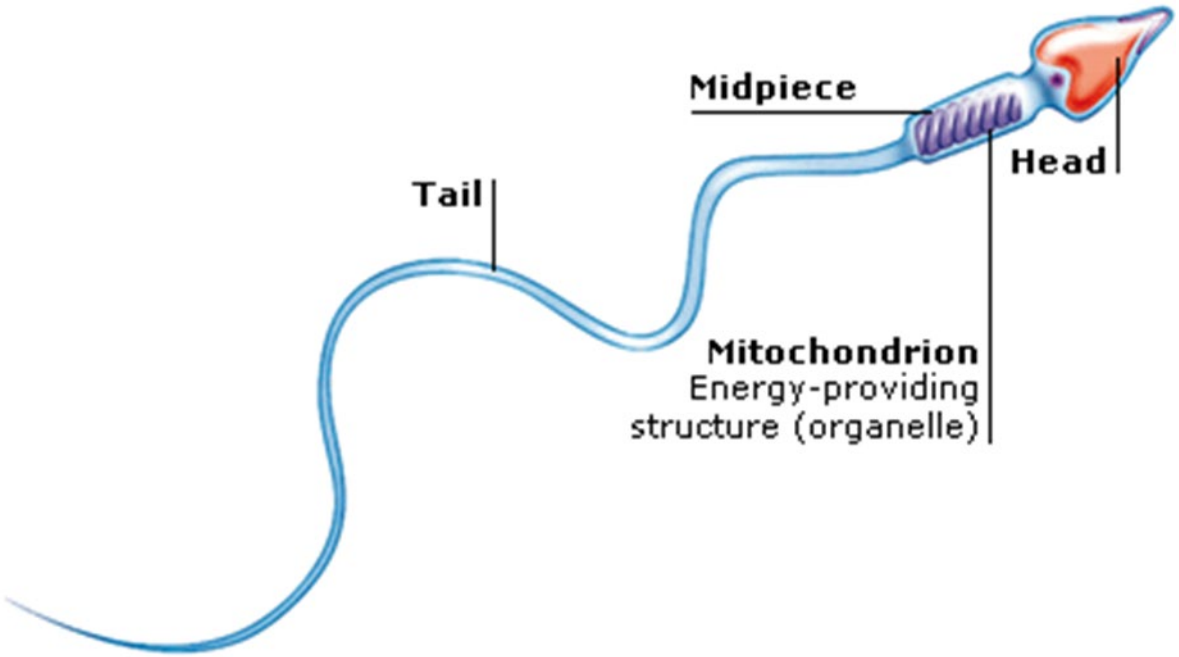



Sperm cell - A sperm is about 1/500 inch long, but most of this is a tail.

The sperm head is only 1/5000 inch, about the same size as a red blood cell.

Sperm develop in the testes and consist of a head, a midpiece, and a tail.

The head contains the nucleus with densely coiled chromatin fibers (chromosomes), with a front section – the Acrosome that contains enzymes for penetrating the female egg.

The midpiece has a central filamentous core with many **Mitochondria** spiraled around it, to give it energy to move the tail which propels it forward.

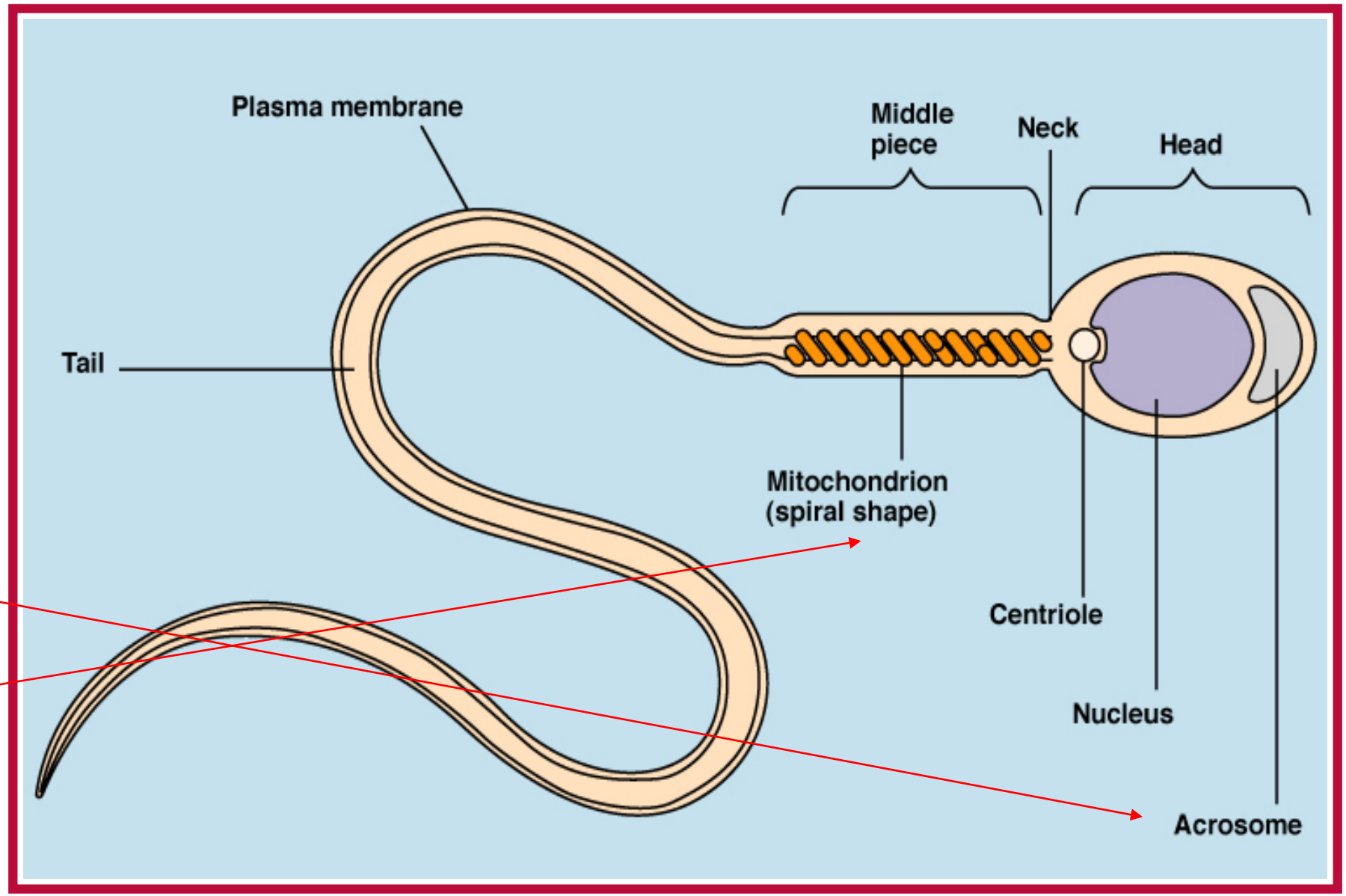

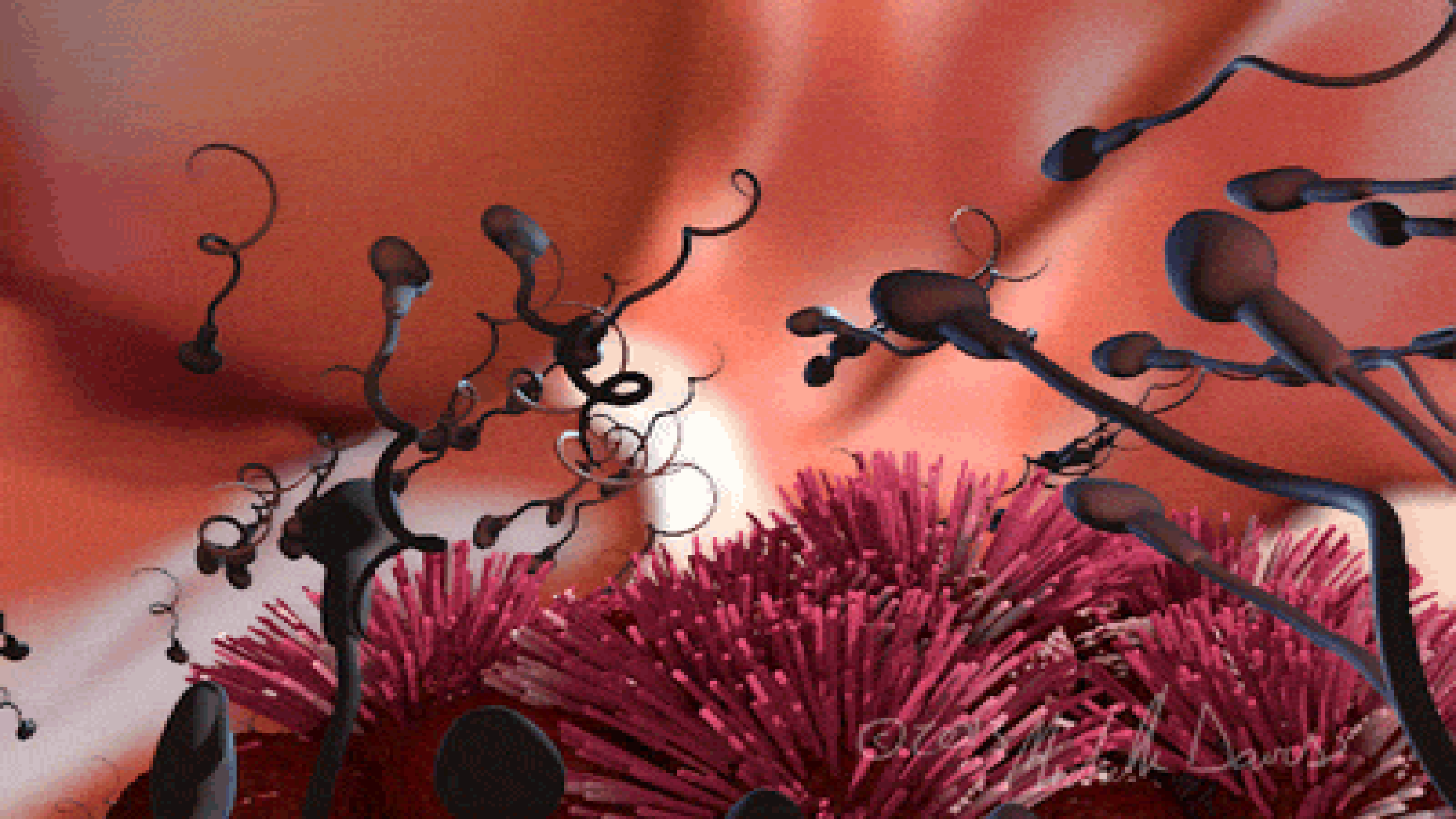

The female reproductive system includes external and internal genitalia.

The vulva and its structures form the external genitalia.

The internal genitalia include a three-part system of ducts: the uterine tubes, the uterus, and the vagina.

This system of ducts connects to the ovaries, the primary reproductive organs.

The ovaries produce egg cells and release them for fertilization.

Fertilized eggs develop inside the uterus.

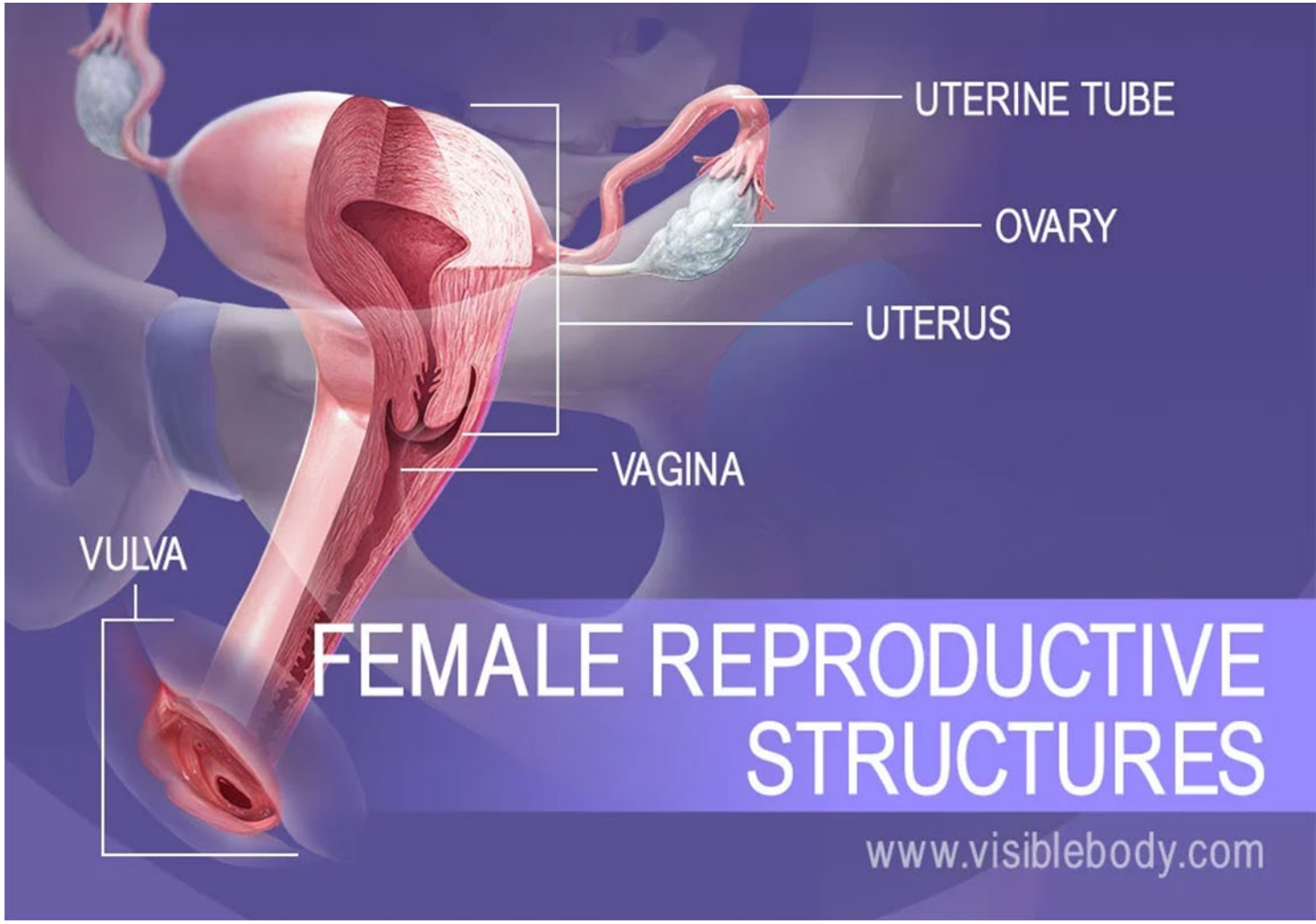

Unlike the male, the female reproductive organs are located entirely inside the body.

From Puberty, their function is to ripen and release an egg at regular intervals, and, if the egg is fertilized, to protect and nourish the embryo and fetus.

No eggs are manufactured after birth – a female is born with a full set.

Reproductive tract

The female reproductive glands (ovaries) are located within the abdomen.

This release occurs roughly once a month as part of the menstrual cycle.

The ripe egg travels along the fallopian tube to the uterus, the muscular sac in which it develops into an embryo and then fetus.

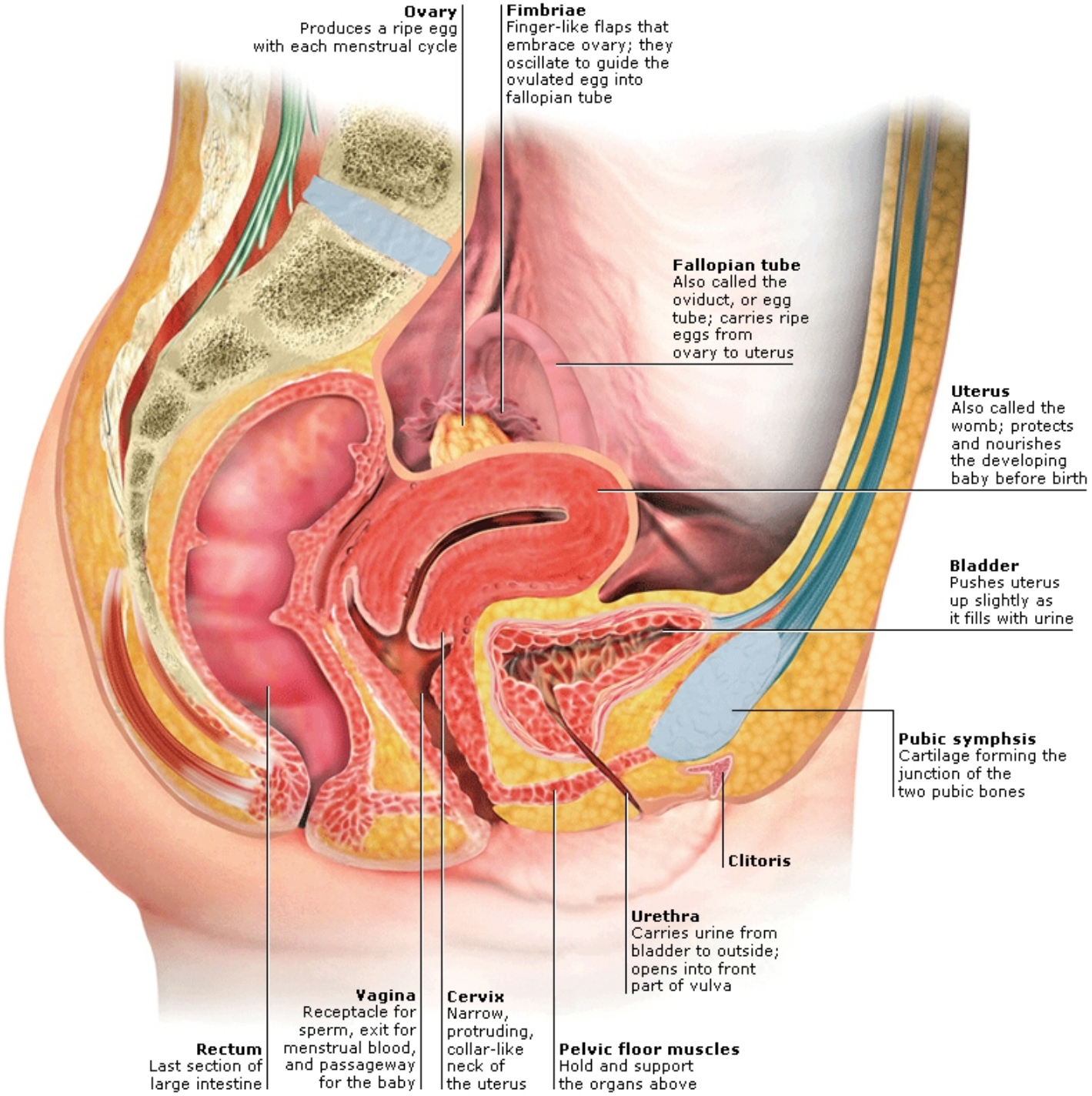

EGG CELLS FROM THE OVARIES MOVE THROUGH THE UTERINE TUBES

The uterine tubes (also called **Fallopian tubes** or **oviducts**) connect the ovaries to the uterus.

The walls of each tube have an external serous layer, a middle muscular layer, and an internal mucous layer that is continuous with the inner lining of the uterus.

Each uterine tube can be divided into three parts:

infundibulum

Isthmus connects with the uterus.

A dilated portion, the **ampulla**, curves over the ovary.

Egg fertilization usually occurs in the ampulla. The eggs then travel through the isthmus into the uterus.

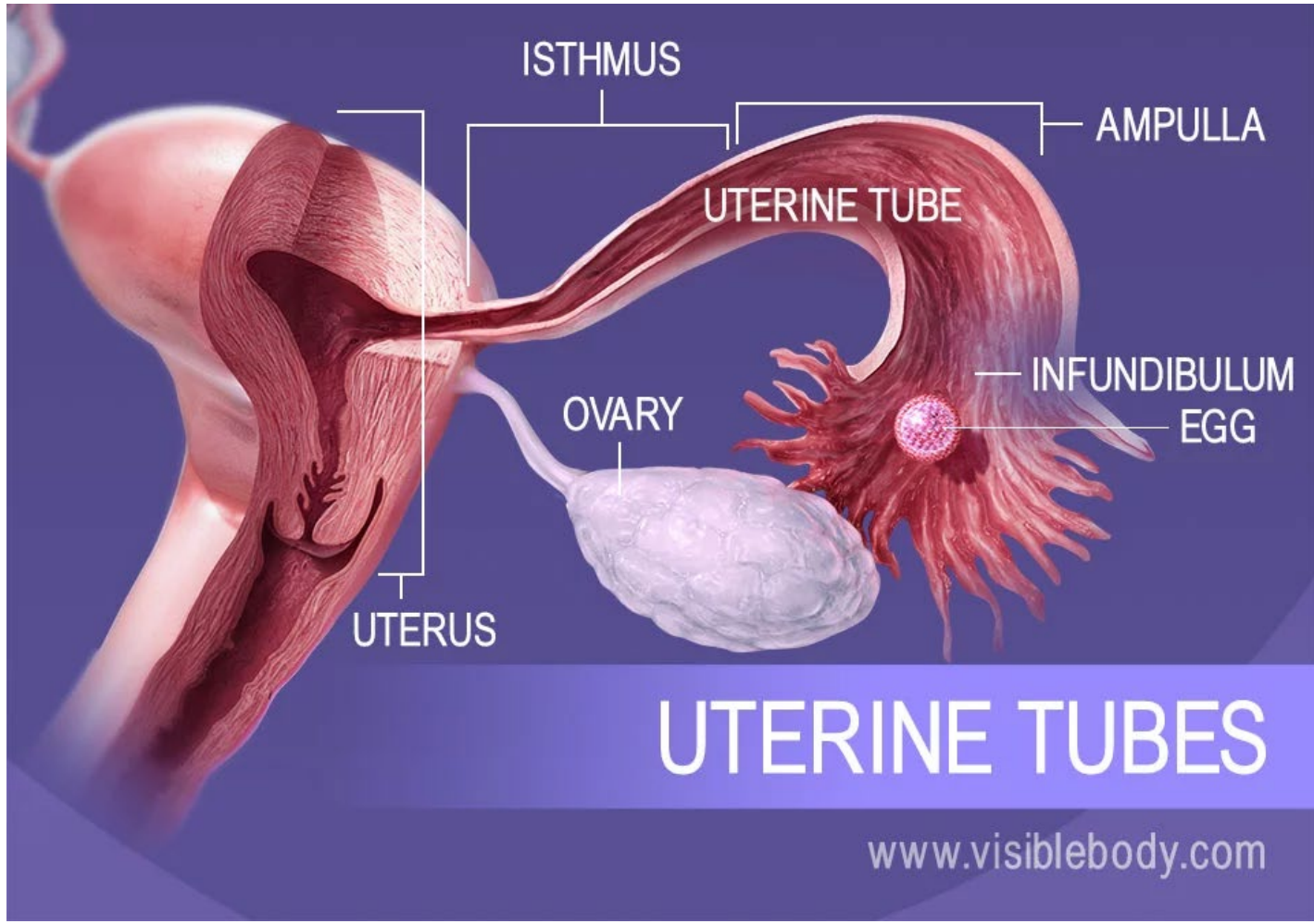

THE VAGINA: A TUNNEL WITH THREE CORE FUNCTIONS

The vagina extends down from the cervix, the lower part of the uterus, to the vestibule, which is part of the vulva and the external genitalia.

It sits behind the bladder and in front of the rectum.

An inner mucous membrane lines the smooth muscle walls of the vagina.

This lining, like the inner layer of the uterine tubes, is continuous with the mucous lining of the uterus.

The vagina has three core functions:

- It carries menstrual flow outside the body
- It receives the male penis during sexual intercourse
- It serves as a birth canal during labor.

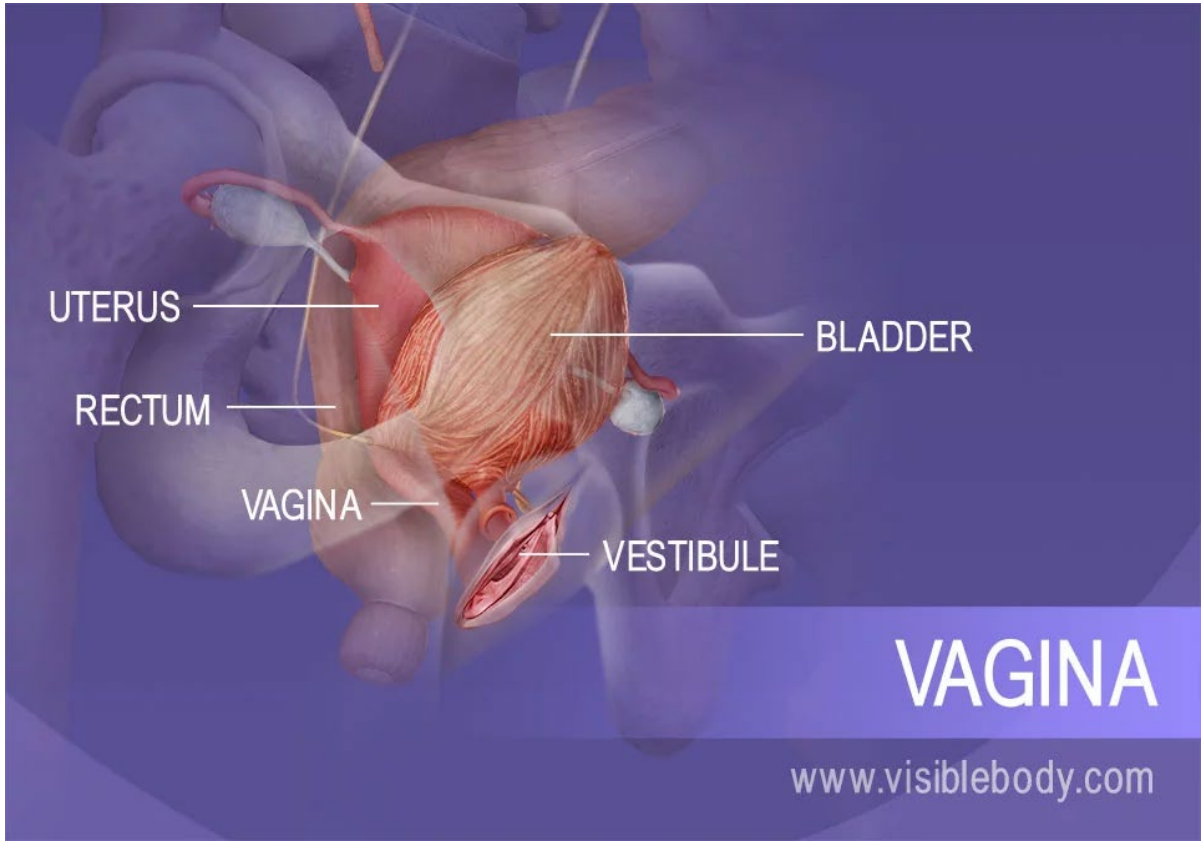

OVULATION

An ovary contains thousands of immature egg cells.

During each menstrual cycle, follicle-stimulating hormone (FSH) causes one egg to begin development; this takes place inside a primary follicle.

The follicle enlarges as its cells proliferate, and begins to fill with fluid, becoming a secondary follicle that moves to the ovary's surface.

It also increases its production of the hormone Estrogen.

A surge of luteinizing hormone (LH) causes the follicle to rupture and release the ripe egg–this is ovulation.

The lining of the empty follicle thickens into a corpus luteum–a temporary source of hormones.

https://www.youtube.com/watch?v=nLmg4wSHdxQ

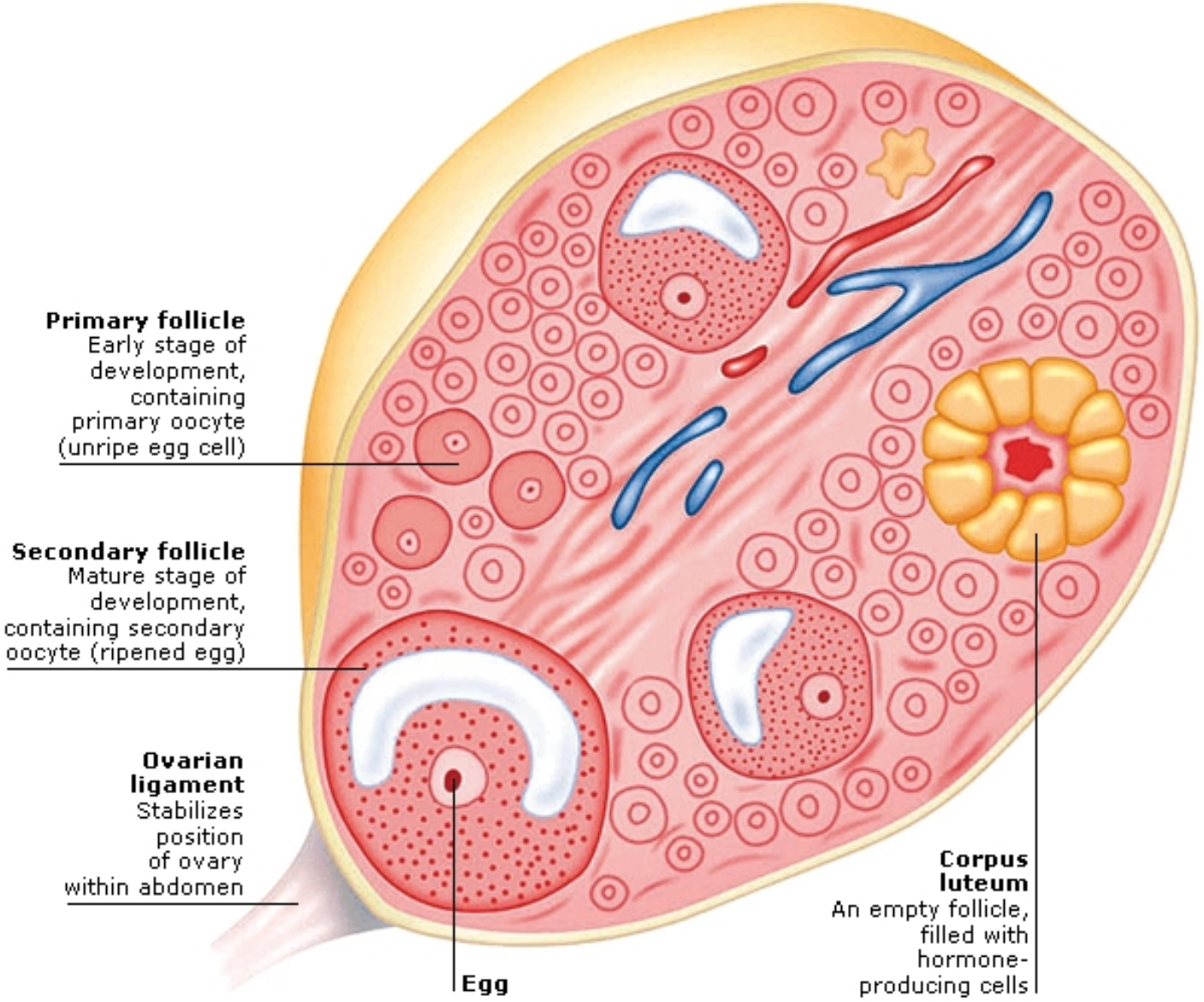

The ovary contains undeveloped eggs, eggs in follicles at various stages of maturation, and empty follicles forming corpora lutea. The bulk of the glandular tissue surrounding these follicles is known as the stroma.

EGG AND SPERM HAVE DEVELOPED SOME PRETTY NIFTY TRICKS TO MAKE CONCEPTION HAPPEN

Fortify the troops - The liquid portion of semen not only provides the sperm with nourishment for the journey, it actually coagulates in a woman's vagina after ejaculation, forming a physical barrier that prevents the sperm from wandering very far in the wrong direction. This protection disappears within half an hour, when the semen becomes more fluid again.

Call in the transport unit - The cervical canal is a much more welcoming environment, and sperm that make it there find themselves awash in a sea of cervical mucus. The mucus is specially designed to transport sperm efficiently when you're most fertile. As you approach ovulation, your suddenly copious mucus becomes stretchy, clear and thin and strings of molecules line up like train tracks so that sperm can hop on and ride to their destination.

Picking up speed - A just-ejaculated sperm cell has to spend a couple of hours going through biochemical changes, picking up tail-thrashing speed to help it make its way into the uterus and fallopian tubes to find its target.

Timing is Important - Sperm must reach their destination within the right time frame for when the egg is there.

They also need to pick their destination carefully - An egg is usually only present in one of the two fallopian tubes in any given month. Pick the wrong tube, and the sperm end up hanging out partying together with no guest of honor in sight.

May the best sperm win!

Note that the egg has 2 layers that the sperm needs to get through – The outer **Corona Radiata** irregular surface and then the **Zona Pellucida** which is a transparent but thicker layer.

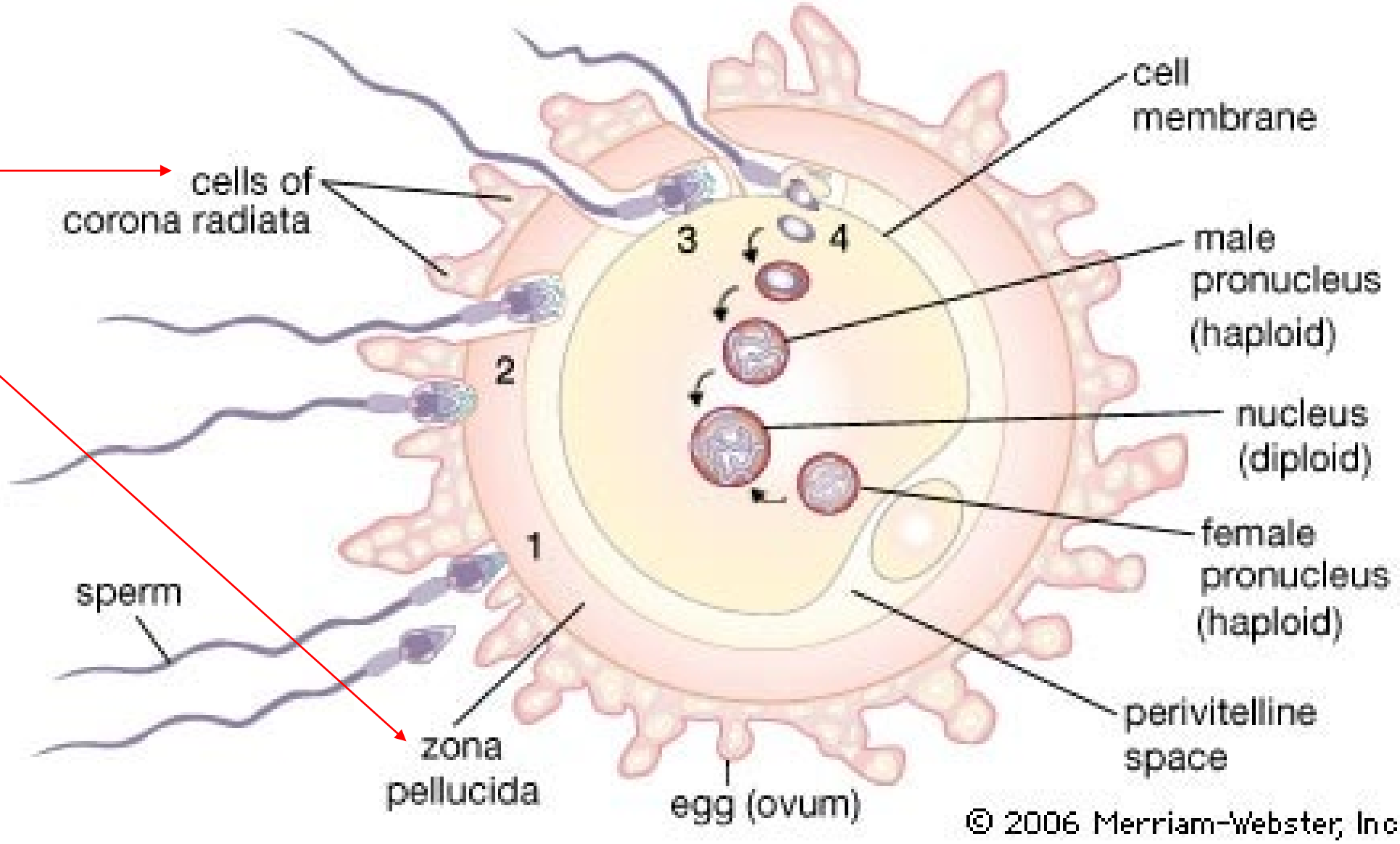

The first sperm to reach the oocyte is never the one to fertilize it.

Rather, hundreds of sperm cells must undergo the acrosomal reaction, each helping to degrade the corona radiata and zona pellucida until a path is created to allow one sperm to contact and fuse with the plasma membrane of the oocyte (egg).

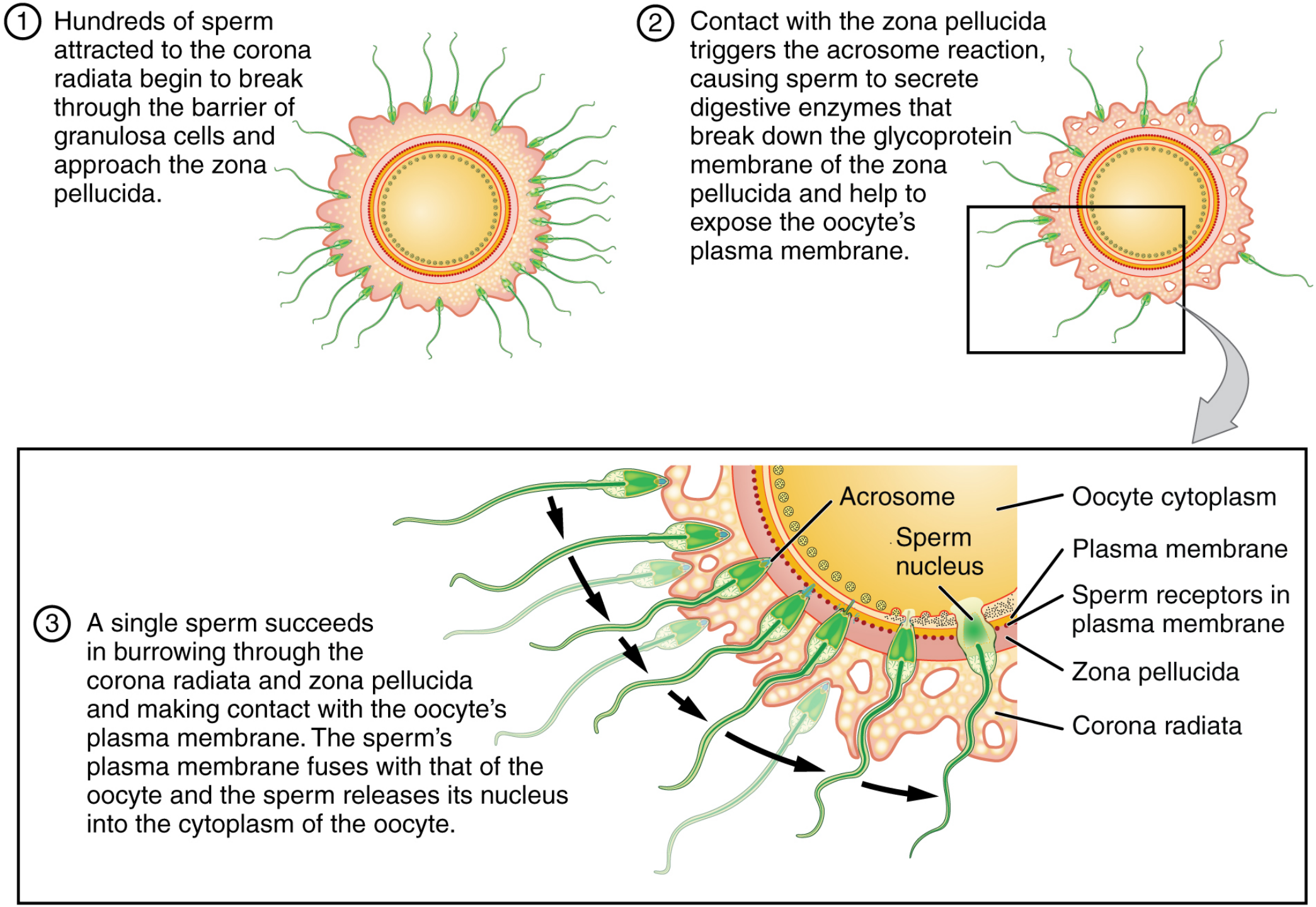

FERTILIZATION: A SPERM AND AN EGG FORM A ZYGOTE

During sexual intercourse, some sperm ejaculated from the male penis swim up through the female vagina and uterus toward an oocyte (egg cell) floating in one of the uterine tubes.

The sperm and the egg are called **gametes**.

They each contain half of the genetic information necessary for reproduction.

When a sperm cell penetrates and fertilizes an egg, that genetic information combines.

The 23 chromosomes from the sperm pair with 23 chromosomes in the egg, forming a 46-chromosome cell called a **zygote**.

The zygote starts to divide and multiply.

As it travels toward the uterus it divides to become a blastocyst, which will burrow into the uterine wall.

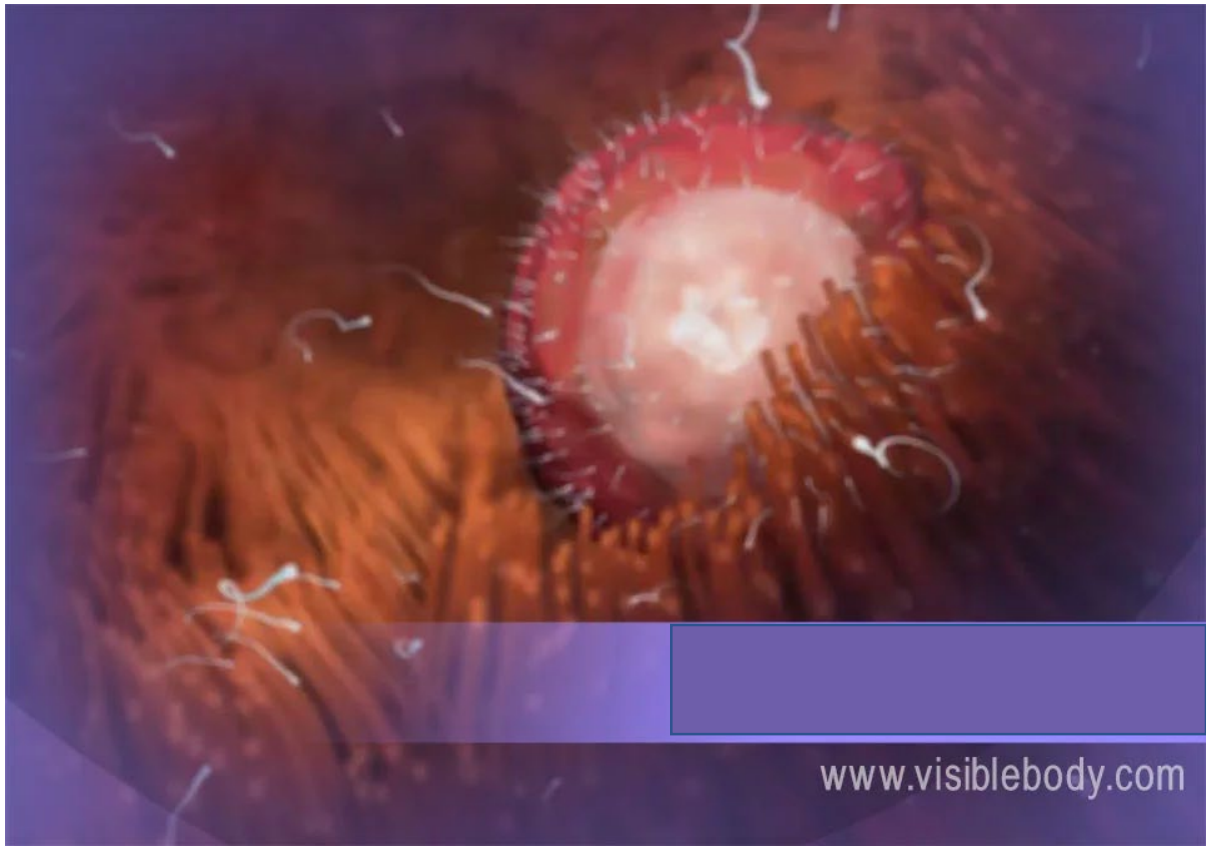

https://www.youtube.com/watch?v=_5OvgQW6FG4

THE ZYGOTE BECOMES AN EMBRYO: DEVELOPMENT PRIOR TO AND DURING IMPLANTATION

A fertilized egg, or zygote, takes about five days to reach the uterus from the uterine tube.

As it moves, the zygote divides and develops into a blastocyst, with an inner mass of cells and a protective outer ring.

The blastocyst attaches to the wall of the uterus and gradually implants itself into the uterine lining. During implantation, its cells differentiate further.

At day 15 after conception, the cells that will form the embryo become an **embryonic disc**. Other cells begin to form support structures.

The **yolk sac**, on one side of the disc, will become part of the digestive tract.

On the other side, the **amnion** fills with fluid and will surround the embryo as it develops.

Other cell groups initiate the placenta and umbilical cord, which will bring in nutrients and eliminate waste.

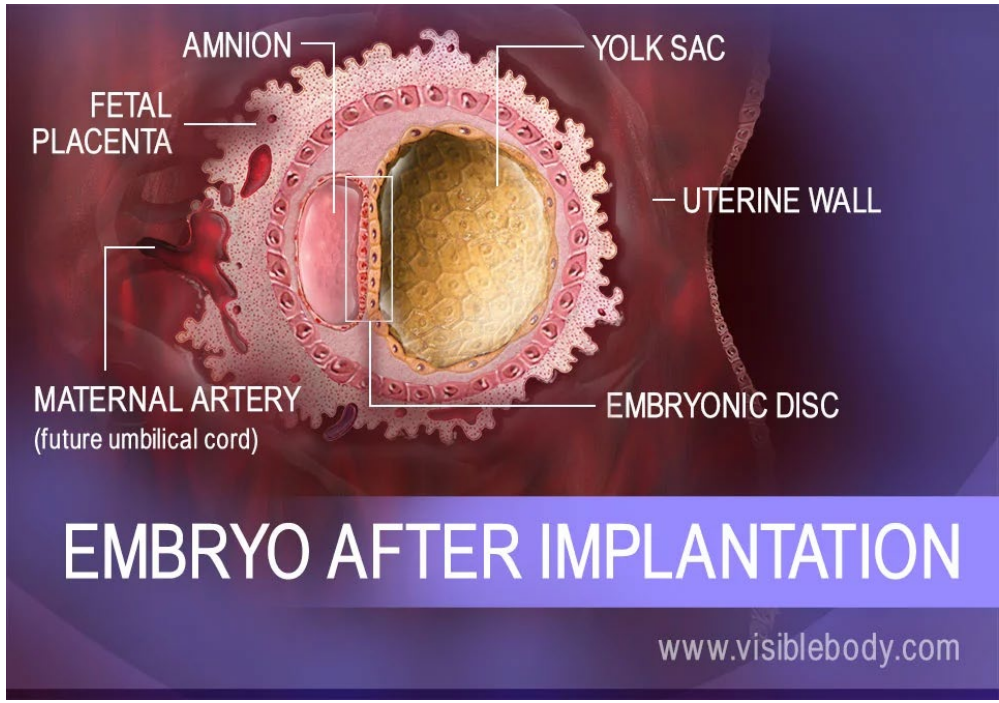

ZYGOTE

The fertilized egg passes along the fallopian tube.

Within 24–36 hours it has divided into two cells, then 12 hours later into four cells, and so on.

This process is known as cleavage.

At each stage, the resulting cells become smaller, gradually approaching normal body cell size.

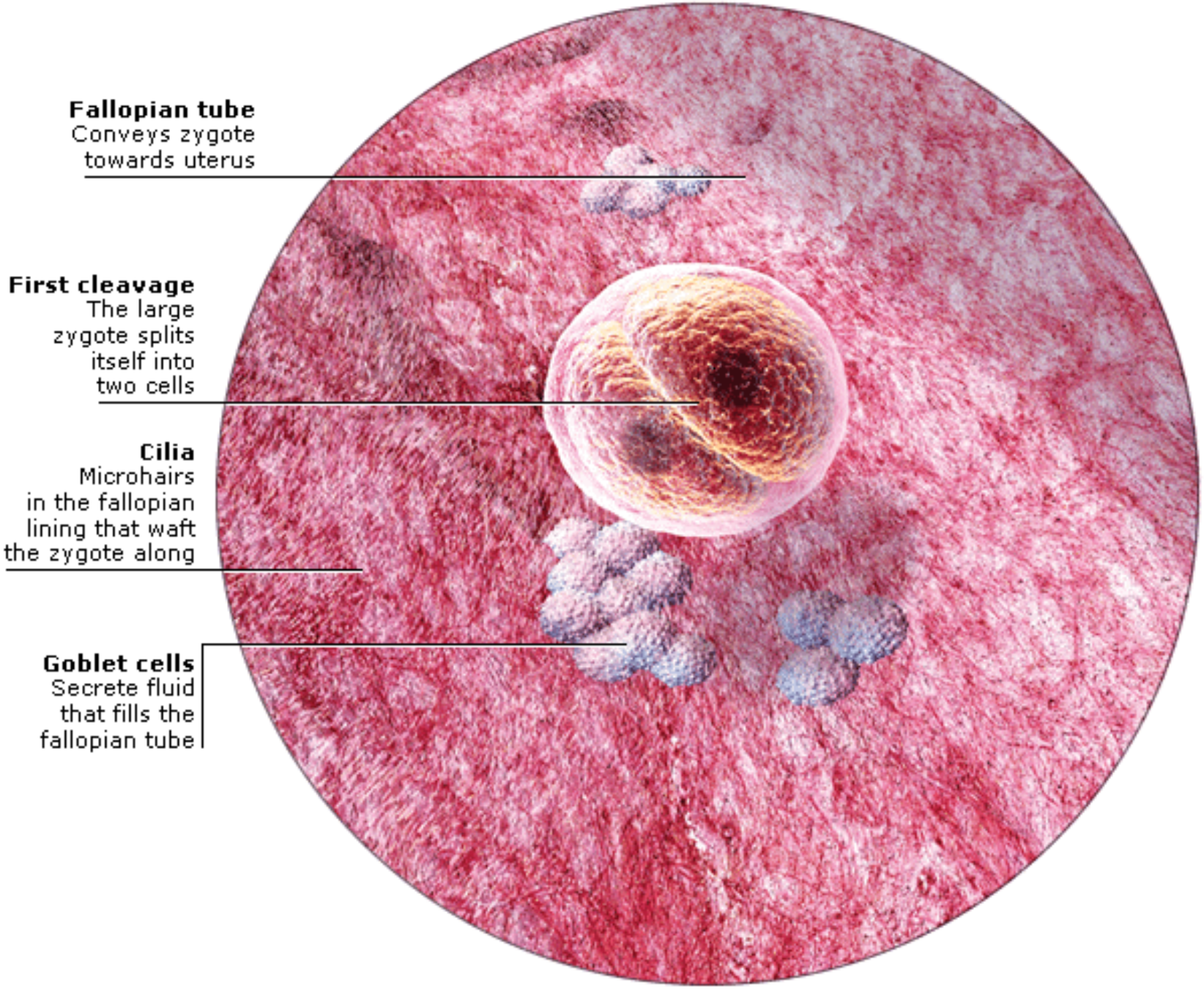

MORULA

The zygote divides several times to form a solid blackberry-like cluster of 16–32 cells, the morula (derived from the Latin for “mulberry”).

At around 3–4 days after fertilization the morula leaves the fallopian tube and enters the uterine cavity.

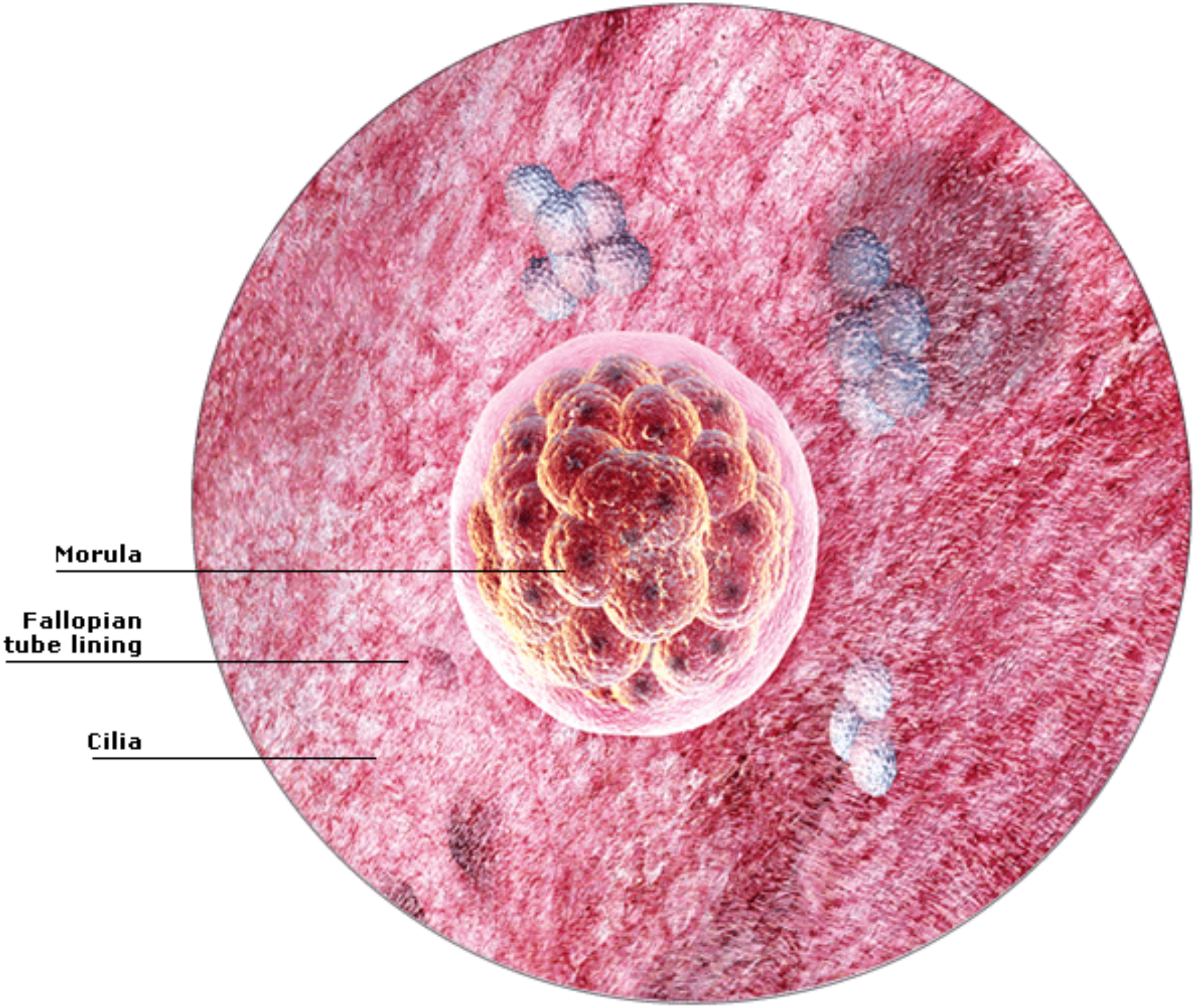

BLASTOCYST

About six days after fertilization, the cell cluster forms a hollow cavity and is known as a blastocyst.

It floats within the uterus for around 48 hours before landing on the thick uterus lining (endometrium), which softens to aid implantation (burrowing of the blastocyst into the endometrium).

The inner group of cells will become the embryo itself.

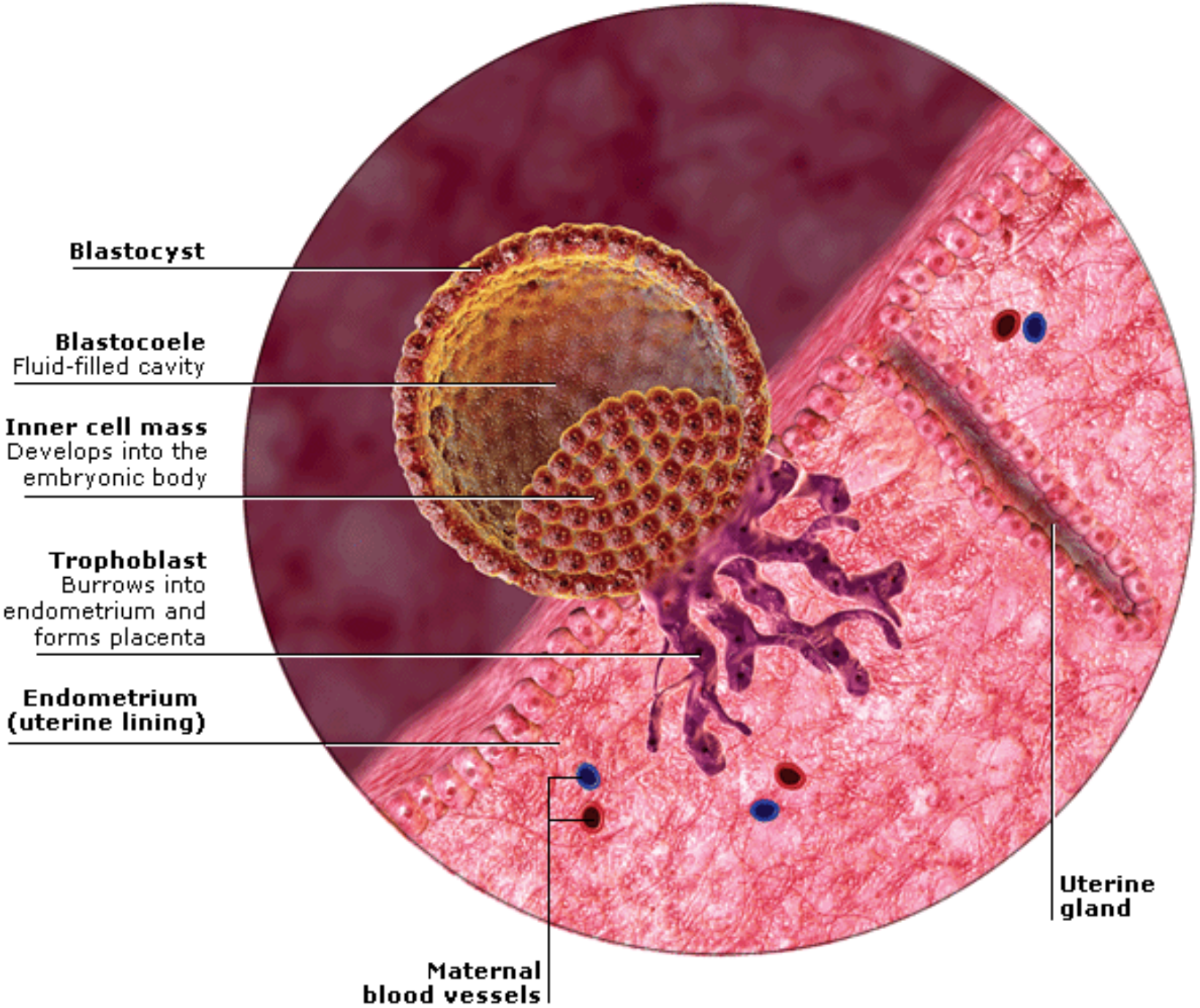

EMBRYONIC DISC

Within the inner cell mass, an embryonic disc forms.

This separates the cell cluster into the amniotic cavity, which develops into a sac that will fill with fluid and fold around to cover the embryo, and the yolk sac, which helps to transport nutrients to the embryo during the second and third weeks.

The disc develops three circular sheets called the primary germ layers –

- **Ectoderm**
- **Mesoderm**
- **Endoderm**

from which all body structures will develop.

https://www.youtube.com/watch?v=dgPCDXmcQjM 5 minutes

https://www.youtube.com/watch?v=UgT5rUQ9EmQ 2.2 minutes

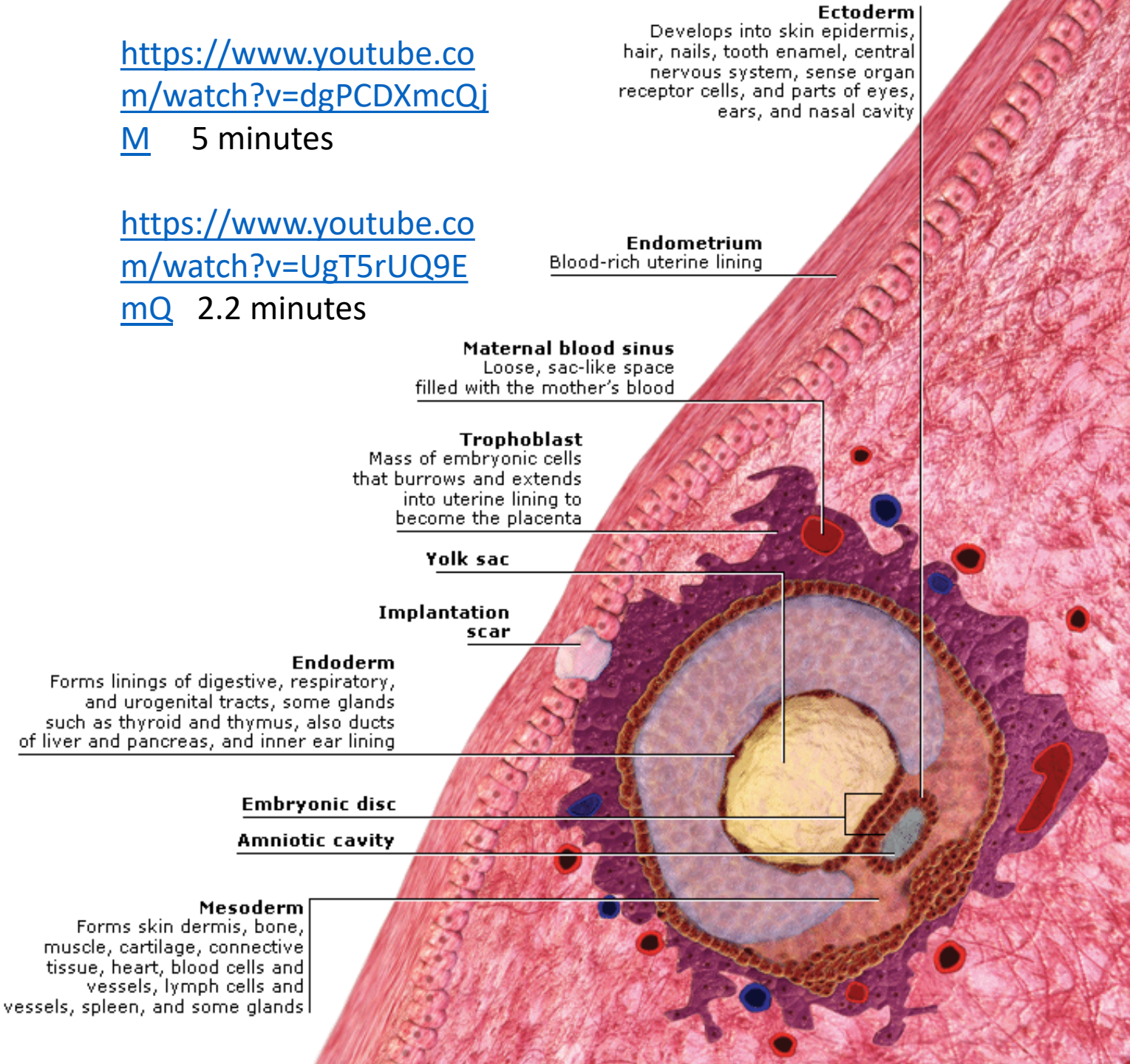

Gastrulation — Mammal

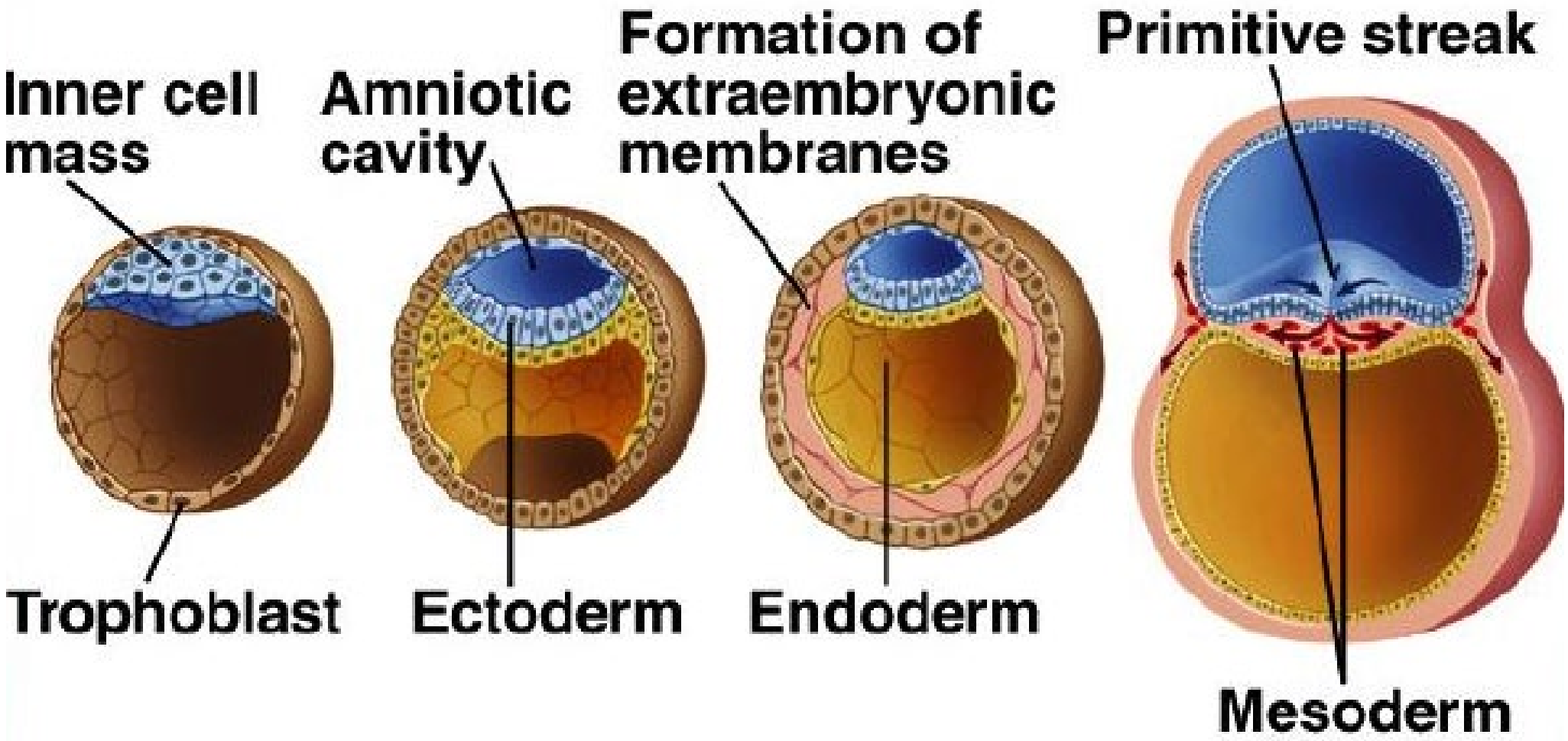

Early in development at the time of gastrulation a small group of cells are "put aside" to later form oocytes (eggs) and sperm. These cells are described as primordial germ cells (PGCs) and are a type of stem cell.

Primordial germ cells, the earliest recognizable precursors of gametes, arise outside the gonads and migrate into the gonads during early embryonic development.

Human primordial germ cells first become readily recognizable at 24 days after fertilization in a layer of the yolk sac.

Germ cells exit from the yolk sac into the hindgut tissue and then migrate until they reach the location of the sex organs.

These cells differentiate at different times into male testis before puberty and female ovary when the girl is young.

GROWING EMBRYO

As development proceeds, cells continue to divide.

They move to form groups that will become tissues and organs.

They also specialize to different cell types, as genes in their chromosomes are switched off or on.

In general, development is head-down, with the brain and head taking shape early, then the body, followed by the arms as small buds, and lastly the legs.

By the end of the embryonic stage, eight weeks after fertilization, all major organs and body parts are formed.

From this time on, the baby is known as a fetus.

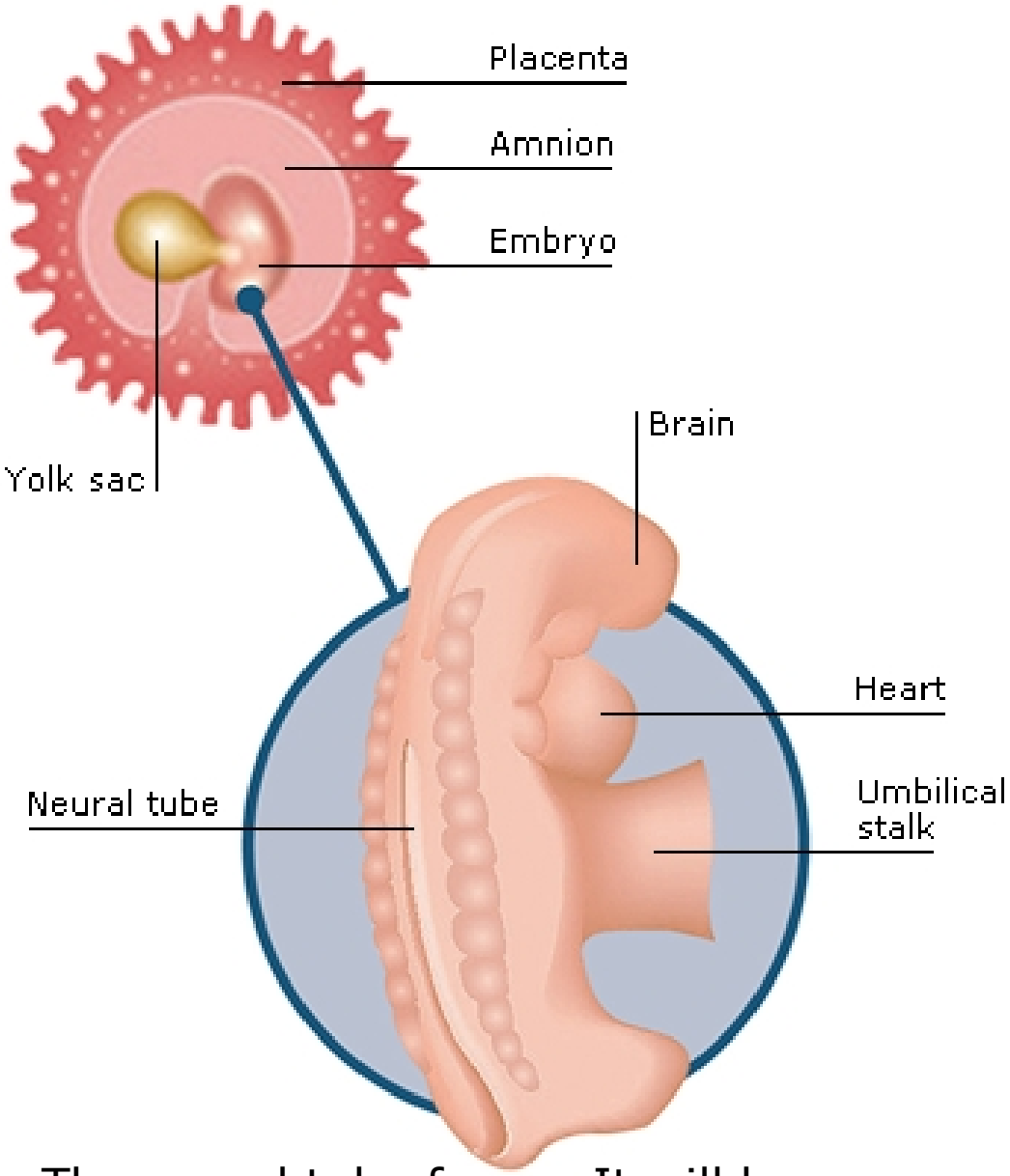

3 weeks - The neural tube forms. It will become the spinal cord, enlarged at one end as the brain. The simple tube-like heart pulsates. The embryo is 4/50– 5/50 inch long.

HUMANS MUST DEVELOP MALE OR FEMALE GONADS AND GENITALIA TO BE CAPABLE OF REPRODUCTION

Reproductive structures begin to form in the embryonic stage.

By week 6, gonads and genitalia are present but undifferentiated. Whether they become male or female is determined by one chromosome delivered by the sperm.

This pair contains an X sex chromosome from the female egg and either an X or a Y sex chromosome from the male sperm.

If the chromosome pair is XY, the gonads develop into testes starting in week 7.

If the chromosome pair is XX, the gonads become ovaries starting in week 8.

Testes secrete testosterone, forming male genitalia around week 10.

Without testosterone, female genitalia form.

All reproductive structures are in place at birth or shortly after.

At puberty, an increase in sex hormones will grow them to their adult size and reproductive capability.

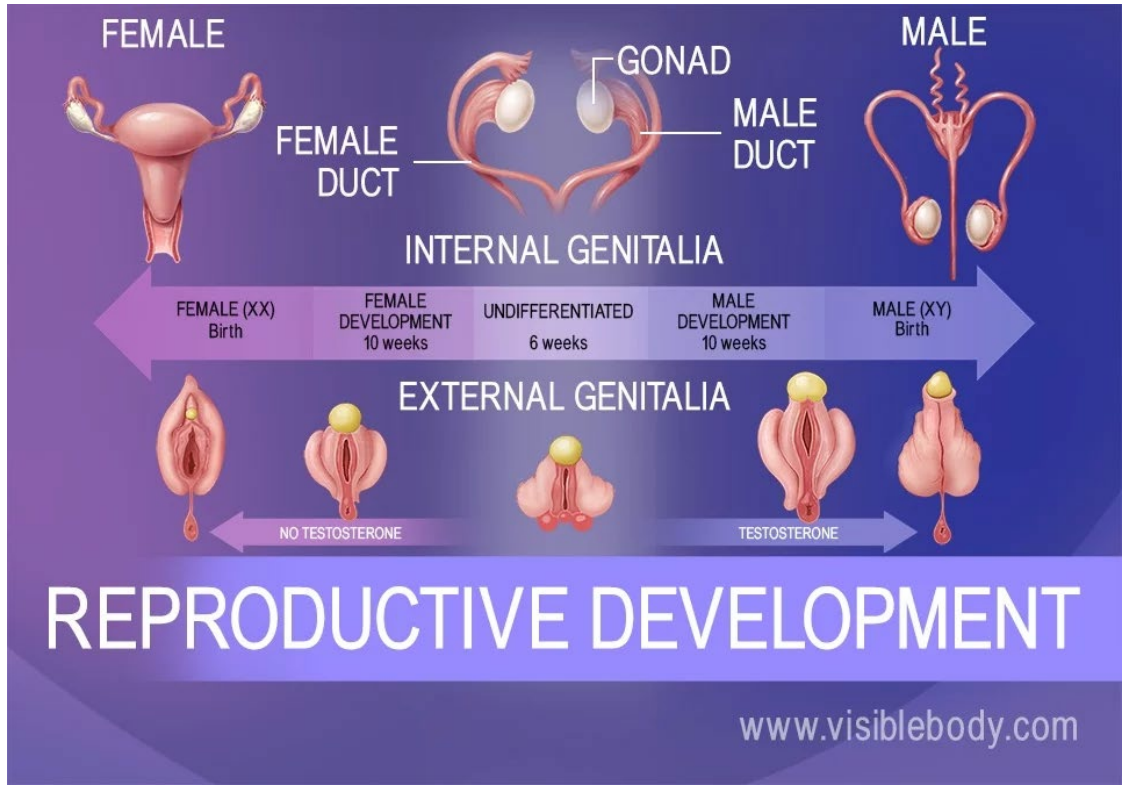

FOUR WEEKS

The four-chambered heart beats, sending blood through simple vessels.

Intestines, liver, pancreas, lungs, and limb buds can be seen.

The embryo is about 1/5 inch long.

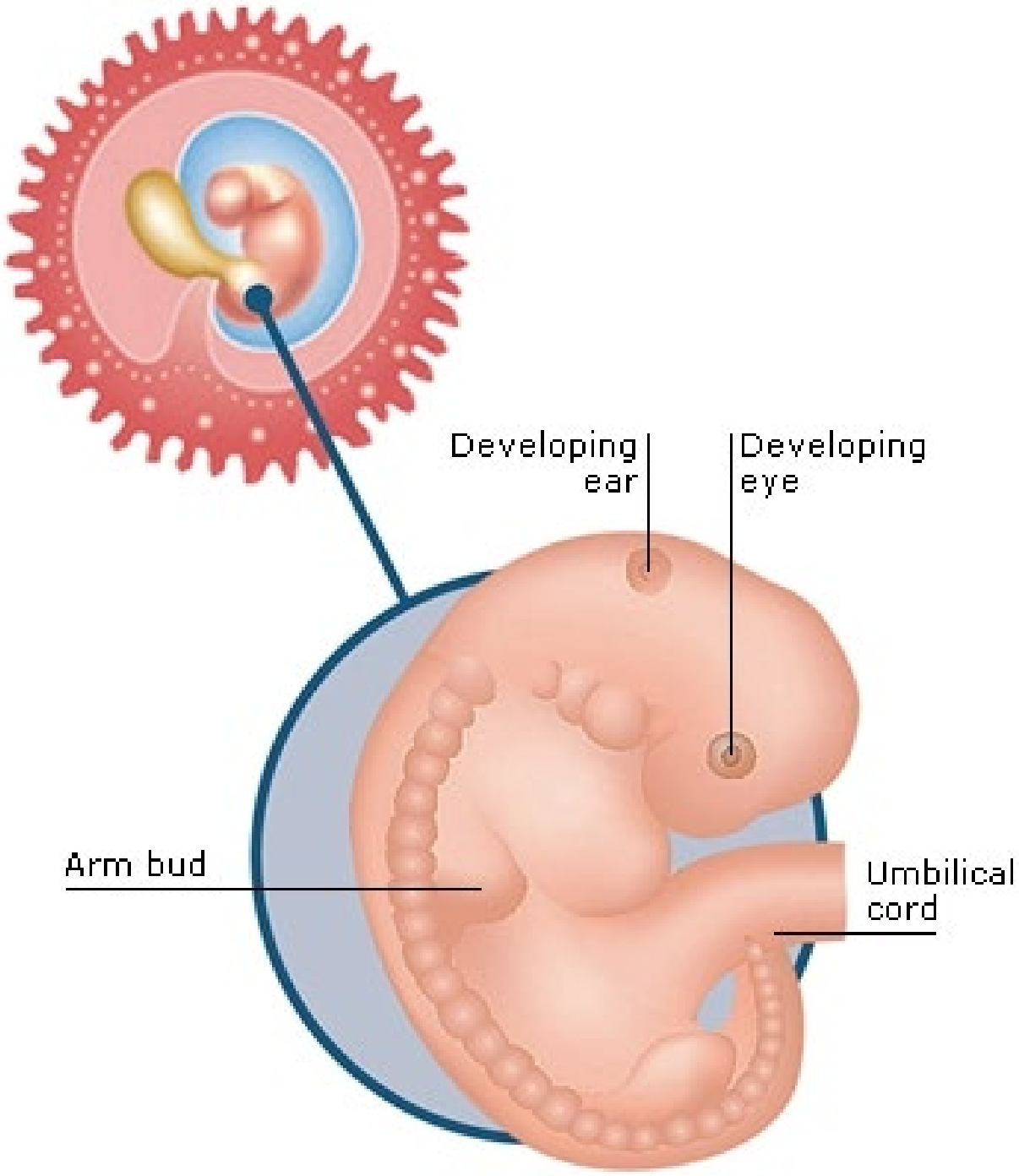

EIGHT WEEKS

At this stage, the face and neck take shape, the back straightens, and fingers and toes can be differentiated clearly.

The embryo starts to move.

It is now around 1 to 1-1/5 inch in length.

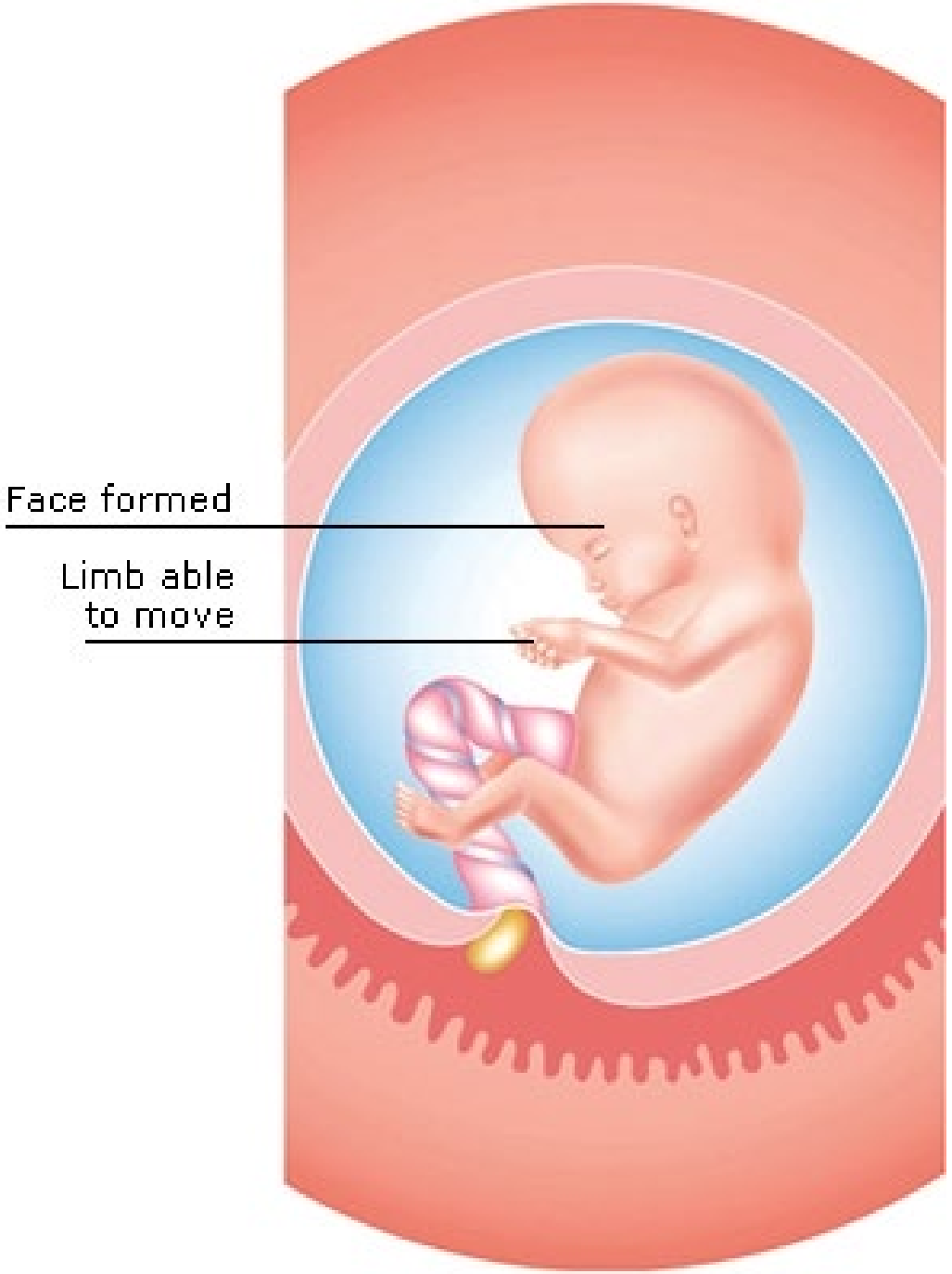

IN EIGHT WEEKS, THE EMBRYO DEVELOPS; BY THE END OF WEEK 10, IT BECOMES A FETUS

Fifteen days after conception marks the beginning of the embryonic period.

The embryo contains a flat embryonic disc that now differentiates into three layers: the endoderm, the mesoderm, and the ectoderm.

All organs of the human body derive from these three tissues.

They begin to curve and fold and to form an oblong body.

By week 4, the embryo has a distinct head and tail and a beating heart.

Over the next six weeks, limbs, eyes, brain regions, and vertebrae form.

Primitive versions of all body systems appear. By the end of week 10, the embryo is a fetus.

This is referring to the gestational age of the fetus.

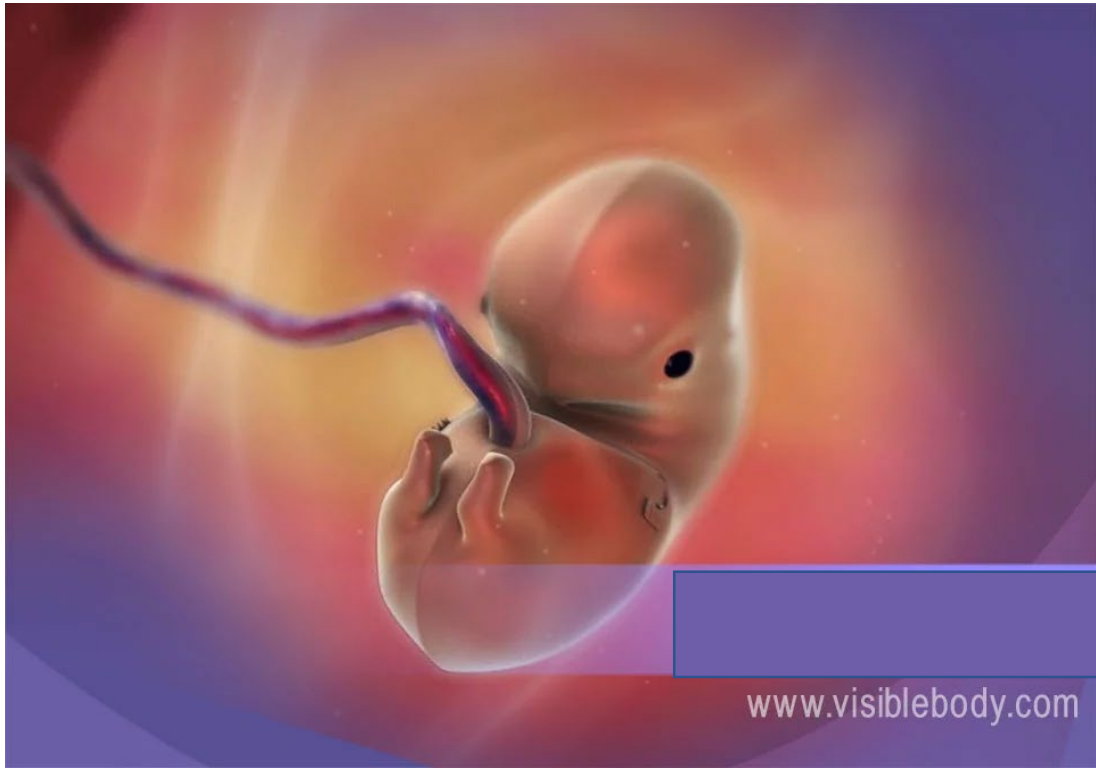

The little groove or **Philtrum** that is in between our nose and upper lip is one of the most important parts of the human face.

The Philtrum or also commonly called as ‘cupid’s bow’ is the hollow space that is in between our nose and our upper lip.

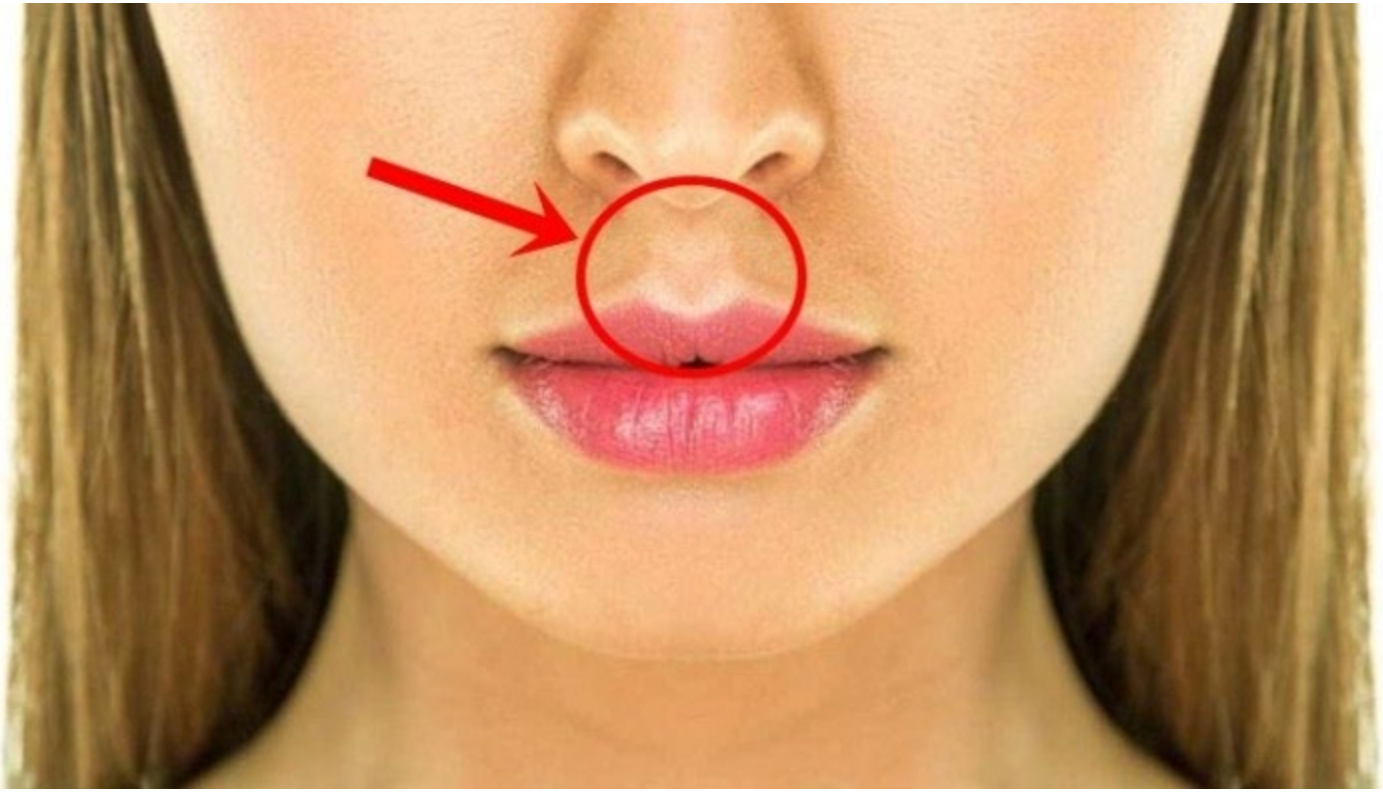

http://www.youtube.com/watch?v=wFY_KPFS3LA

CHANGES IN THE FETUS

By 12 weeks the fetus has a large head compared with the rest of its body, but its features are distinctly human.

- All major internal organs are developed, and even tiny nails exist as folds growing on the fingers and toes.
- The external ears, eyelids, and 32 permanent tooth buds have also formed.
- One month later, rapid development allows the fetus to move its limbs vigorously, although this is rarely felt by the mother at this stage.
- The external genitalia are visible, and a fine downy hair (lanugo) grows over the body.
- As growth continues, the fetus becomes leaner and wrinkly, but by the seventh to eighth month it starts to accumulate fat and assume the "chubby" appearance of the newborn.
- The fetus is now somewhat restricted by the uterus. The side of the placenta facing the fetus is smooth and circular in outline, with the umbilical cord attached at center.

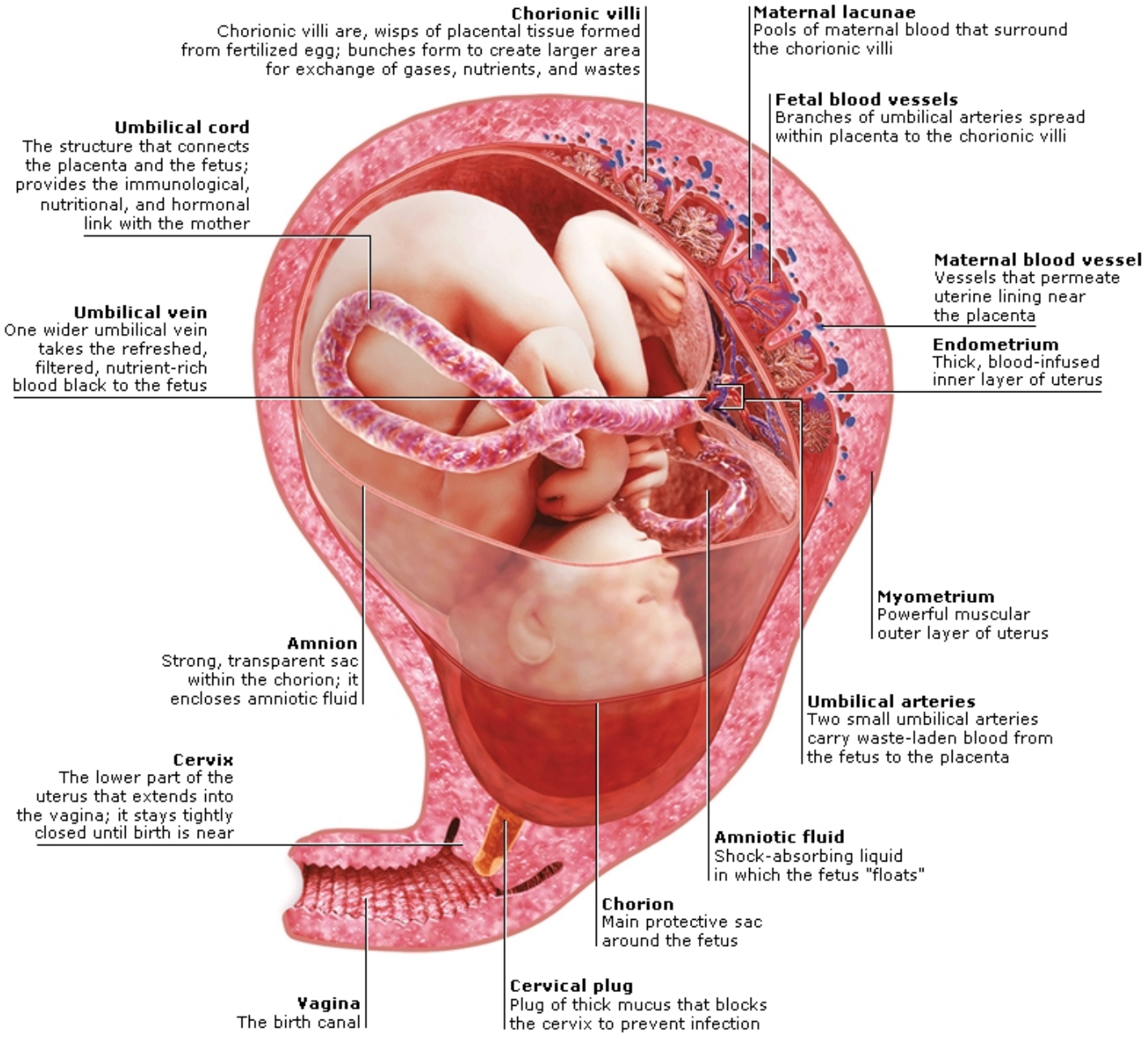

CHANGES IN THE MOTHER

FIRST TRIMESTER

On average, pregnancy lasts for 40 weeks from the first day of a woman's last menstrual period (usually 38 weeks from fertilization).

By convention, the duration of pregnancy is divided into thirds, or trimesters, each lasting for about three calendar months.

During this time, the mother's body undergoes many changes to support the developing fetus, accommodate its increasing size, and prepare itself for childbirth and breast-feeding.

Breasts become tender and larger, with darkened areolas; frequency of urination may increase; nausea and vomiting are common.

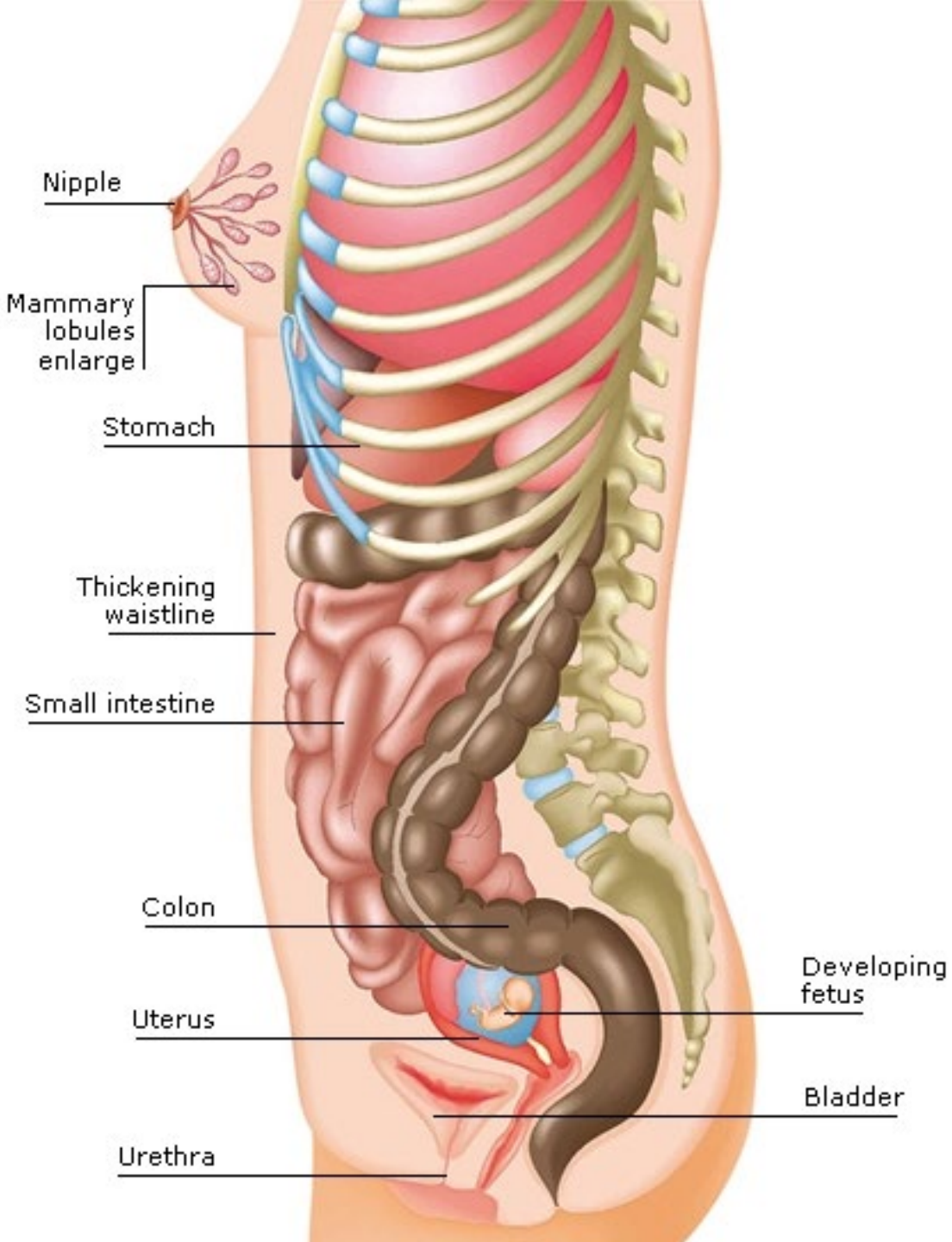

SECOND TRIMESTER

The enlarging uterus shows

Heart rate increases

The mother's forehead and cheek skin may temporarily darken (known as the "mask of pregnancy")

From week 10 of pregnancy, the fetus grows inside the uterus, fueled by nutrient-rich blood supplied by the umbilical cord.

The placenta provides oxygen and nutrients to the fetus and removes waste products from the fetus' blood.

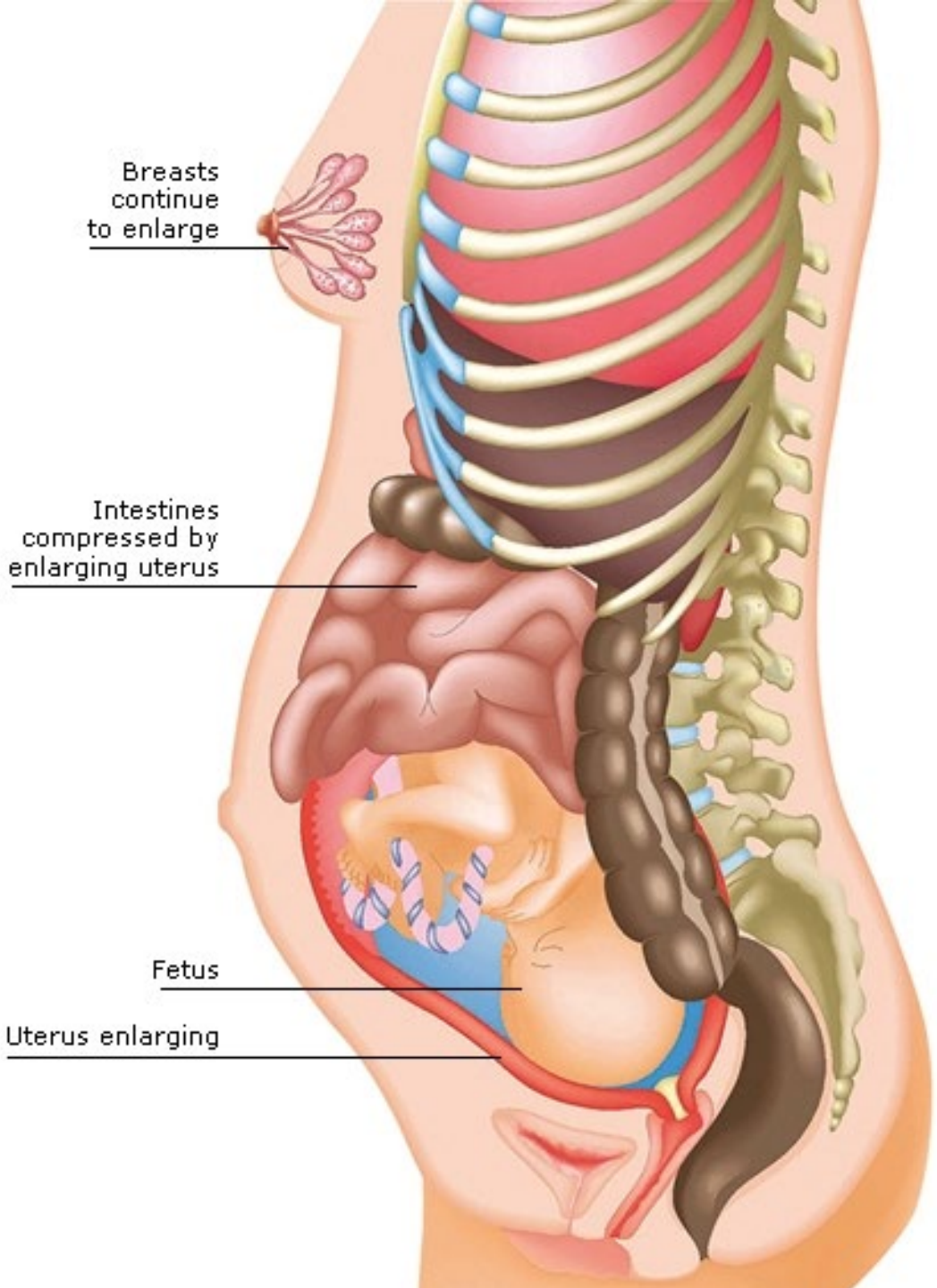

THIRD TRIMESTER

Skin stretches over the abdomen

Slight contractions may be felt

Fatigue, back pain, heartburn, and occasional breathlessness may occur.

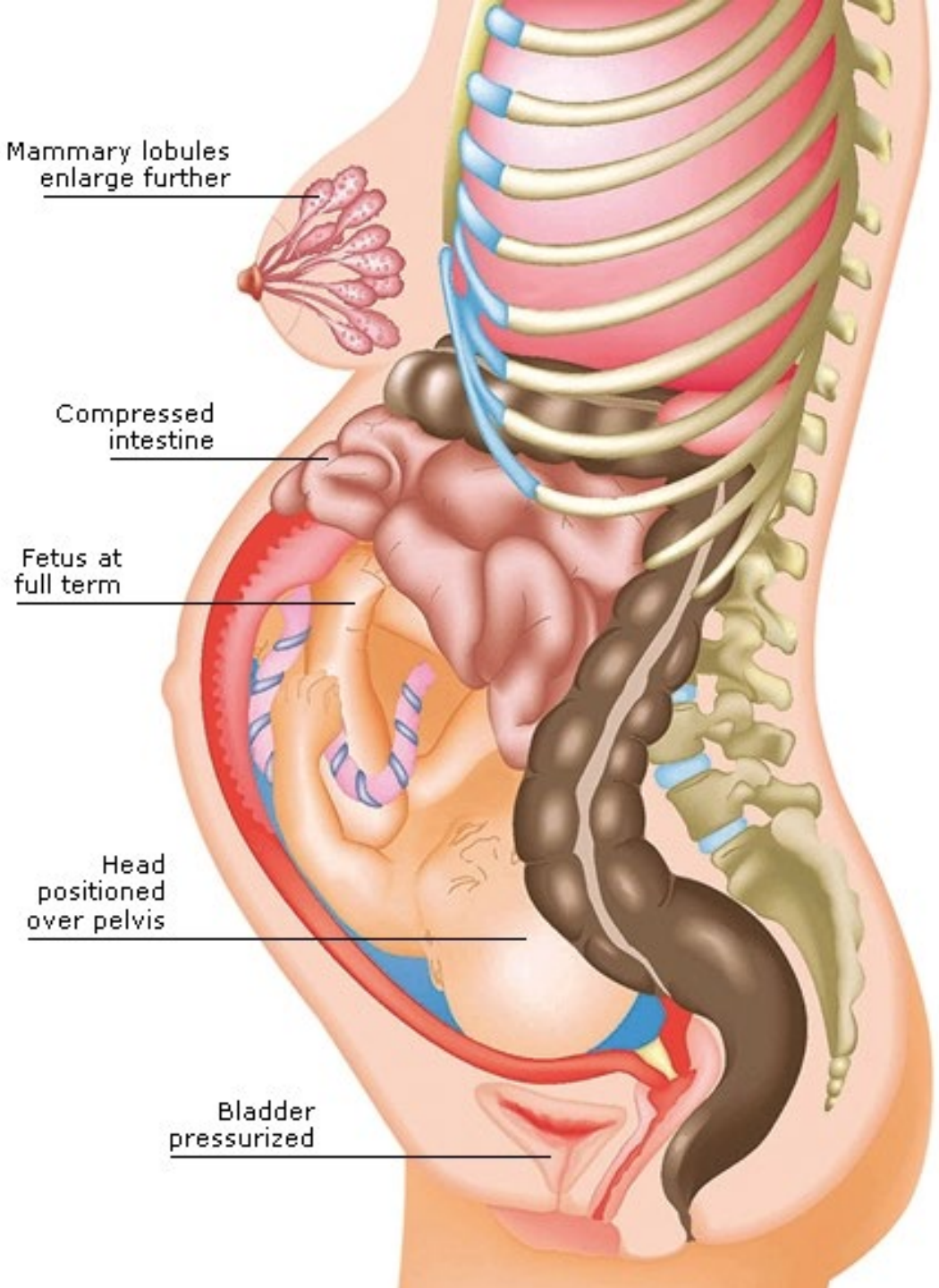

MULTIPLE PREGNANCY AND FETAL POSITIONS

The presence of more than one fetus in the uterus is called a multiple pregnancy.

Twins occur in about one in 80 pregnancies, and triplets in about one in 8,000.

Both events are becoming more common, partly due to improved antenatal care and also increasing use of fertility methods such as IVF (in vitro fertilization).

After about 30 weeks, the most common fetal position is head down, facing the mother's back, with the neck flexed forward.

Such a position eases passage through the birth canal.

However, about 1 in 30 full-term deliveries is breech, in which the baby's buttocks emerge before the head.

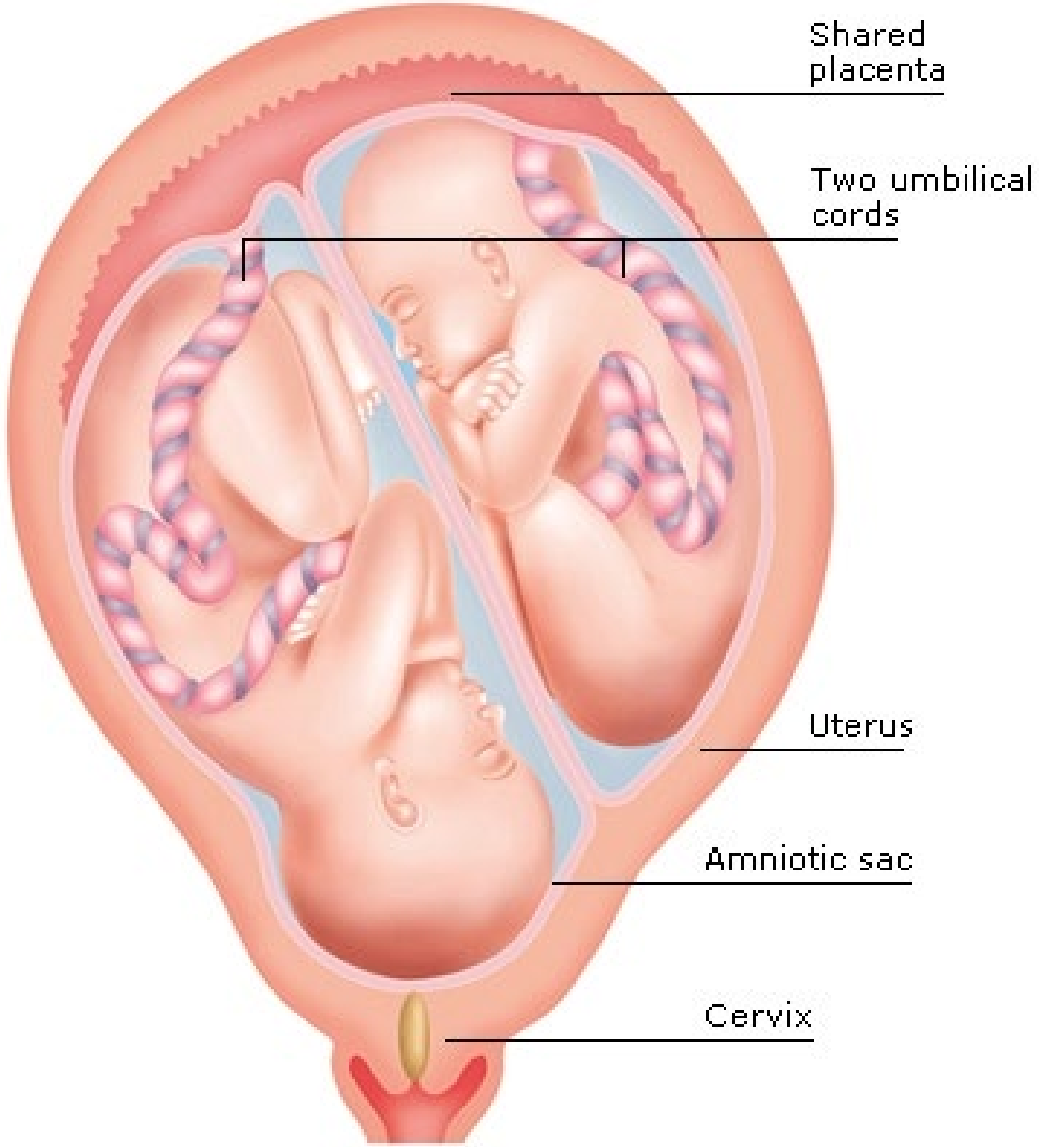

Monozygotic twins - A single fertilized egg, or zygote, forms an embryo that splits into two. Each develops into a fetus. The two have the same genes and sex and share one placenta. They look alike and are known as "identical" twins.

DIZYGOTIC TWINS

Most of the time, a woman releases a single egg during an ovulation cycle.

However, in approximately 1 percent of ovulation cycles, two eggs are released and both are fertilized.

Two zygotes form, implant, and develop, resulting in the birth of dizygotic (or fraternal) twins. Because dizygotic twins develop from two eggs fertilized by two sperm, they are no more identical than siblings born at different times.

Two eggs are fertilized and develop separately, each with its own placenta.

They may be different or the same sex.

Also called “fraternal twins”, they have the same degree of resemblance as any brothers and sisters.

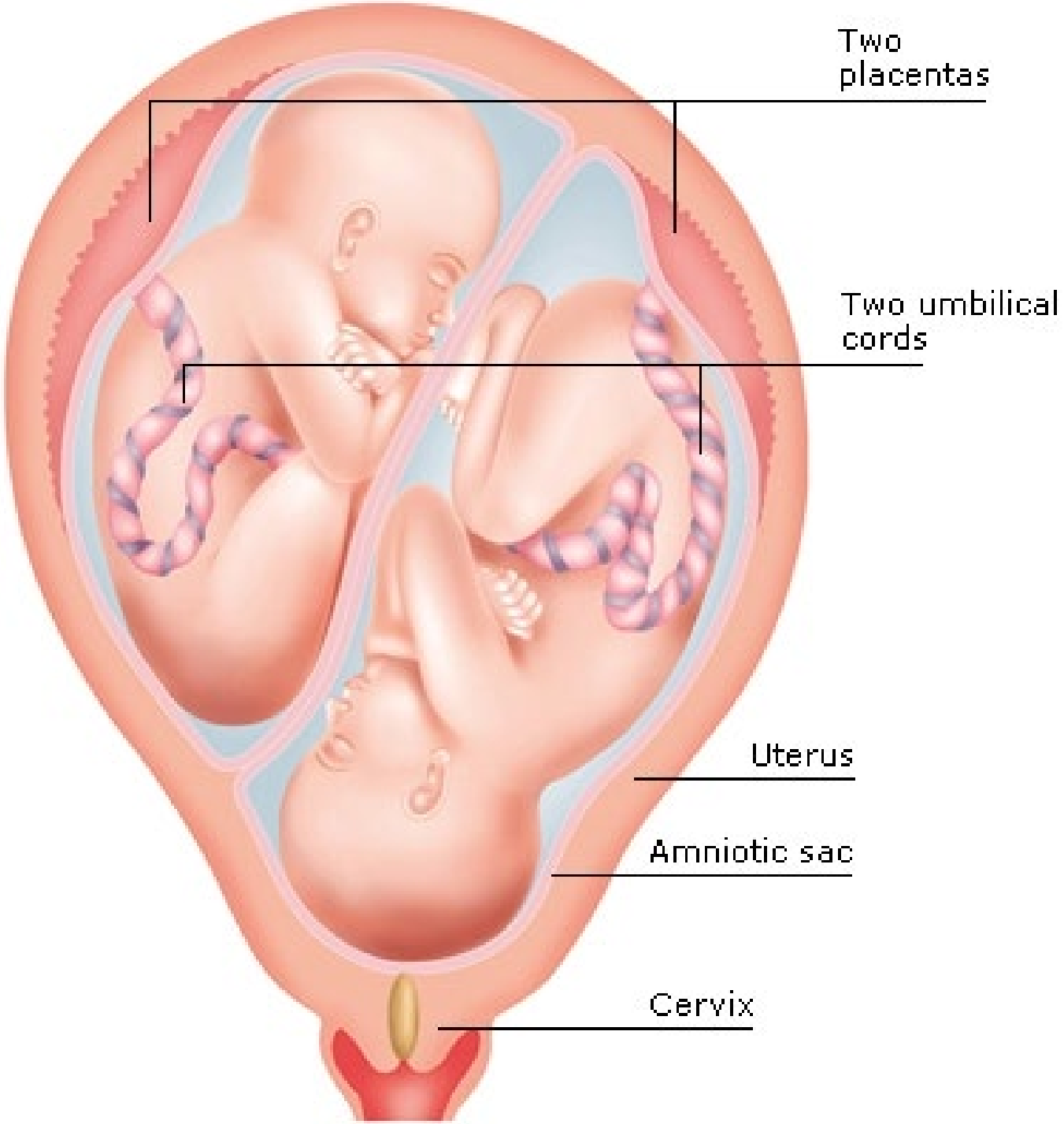

FRANK BREECH

In frank breech, also called incomplete breech, the baby fails to turn head-down in the uterus.

The hips are flexed and the legs are straight, extending alongside the body so that the feet are positioned beside the head.

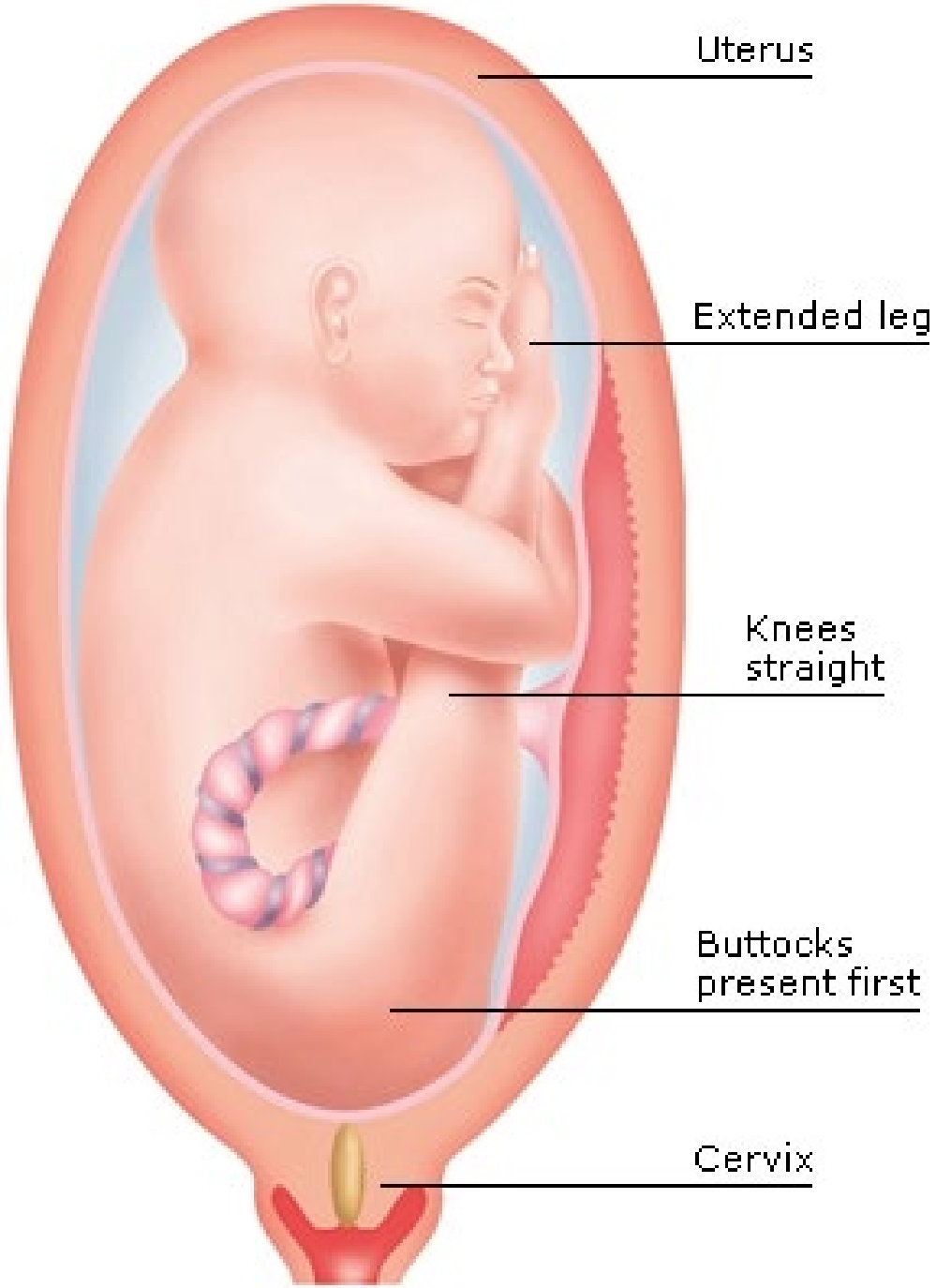

COMPLETE BREECH

The baby's legs are flexed at the hips and knees, so the feet are next to the buttocks.

This occurs less commonly than frank breech.

The incidence of breech delivery is much higher among premature babies.

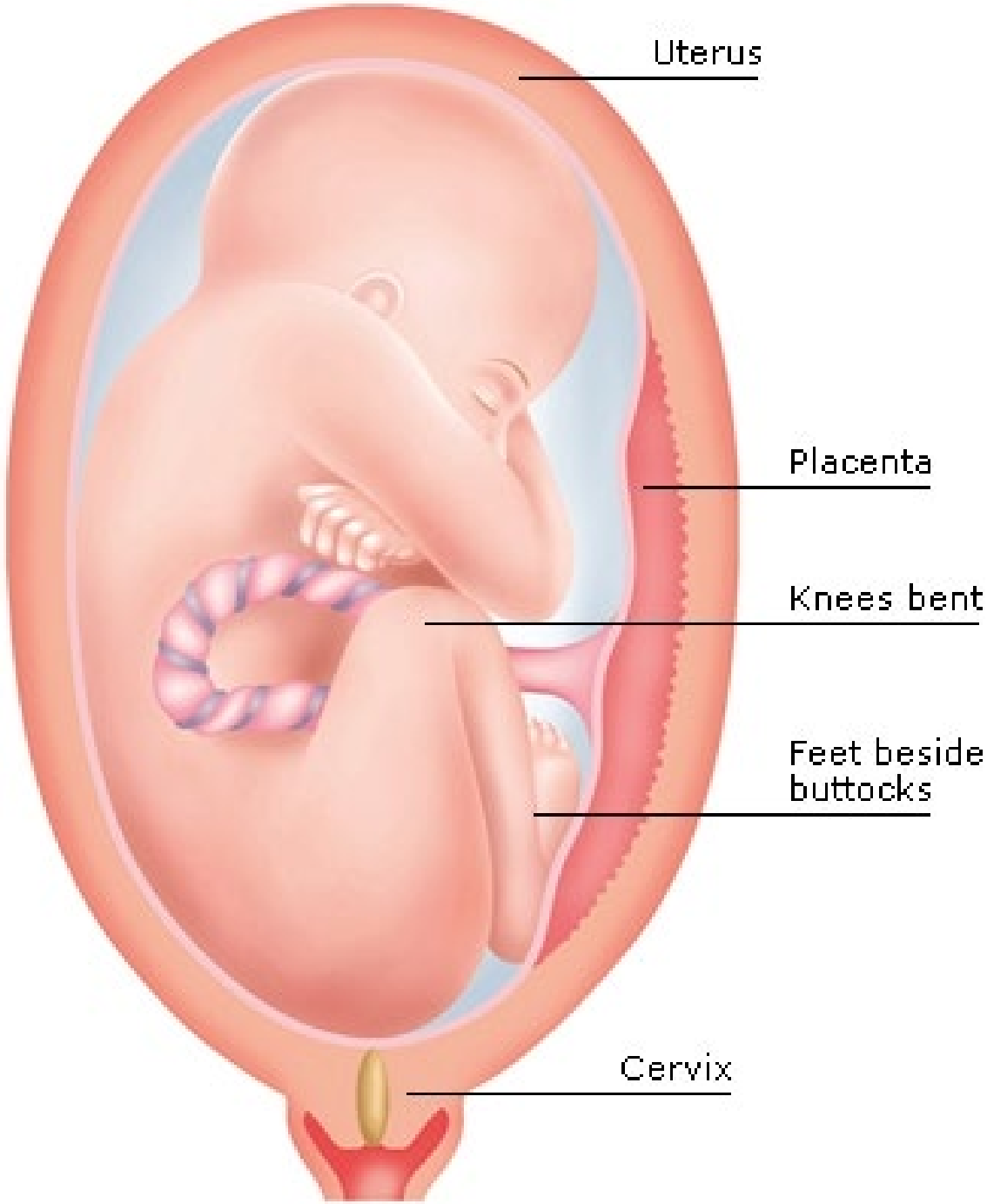

CHANGES IN THE CERVIX

The cervix is the firm band of muscle and connective tissue that forms the neck-like structure at the bottom of the uterus.

In late pregnancy, the cervix softens in readiness for childbirth.

Sporadic uterine tightenings, known as Braxton–Hicks contractions, help to thin the cervix so that it merges with the uterus's lower segment.

Braxton–Hicks contractions are usually painless, and occur through much of pregnancy, becoming noticeable only after mid-term.

Cervix softening
As labor nears, the cervix tissues lose their firm consistency. They become softer and more spongy, affected by natural substances in the blood called prostaglandins.

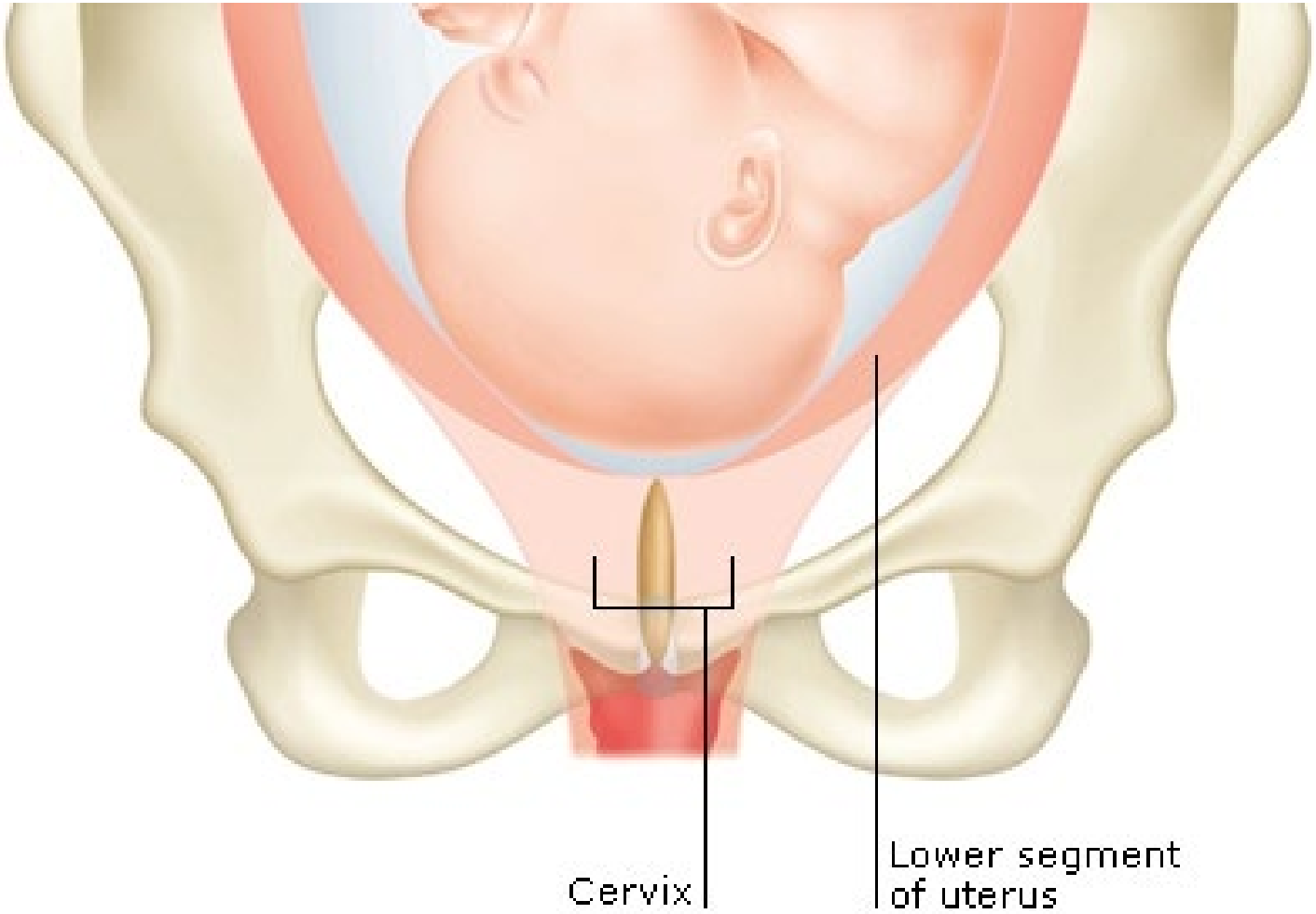

CERVIX THINNING

The cervix becomes wider and thinner, and merges smoothly into the uterus wall above.

The process of softening and thinning is known as effacement.

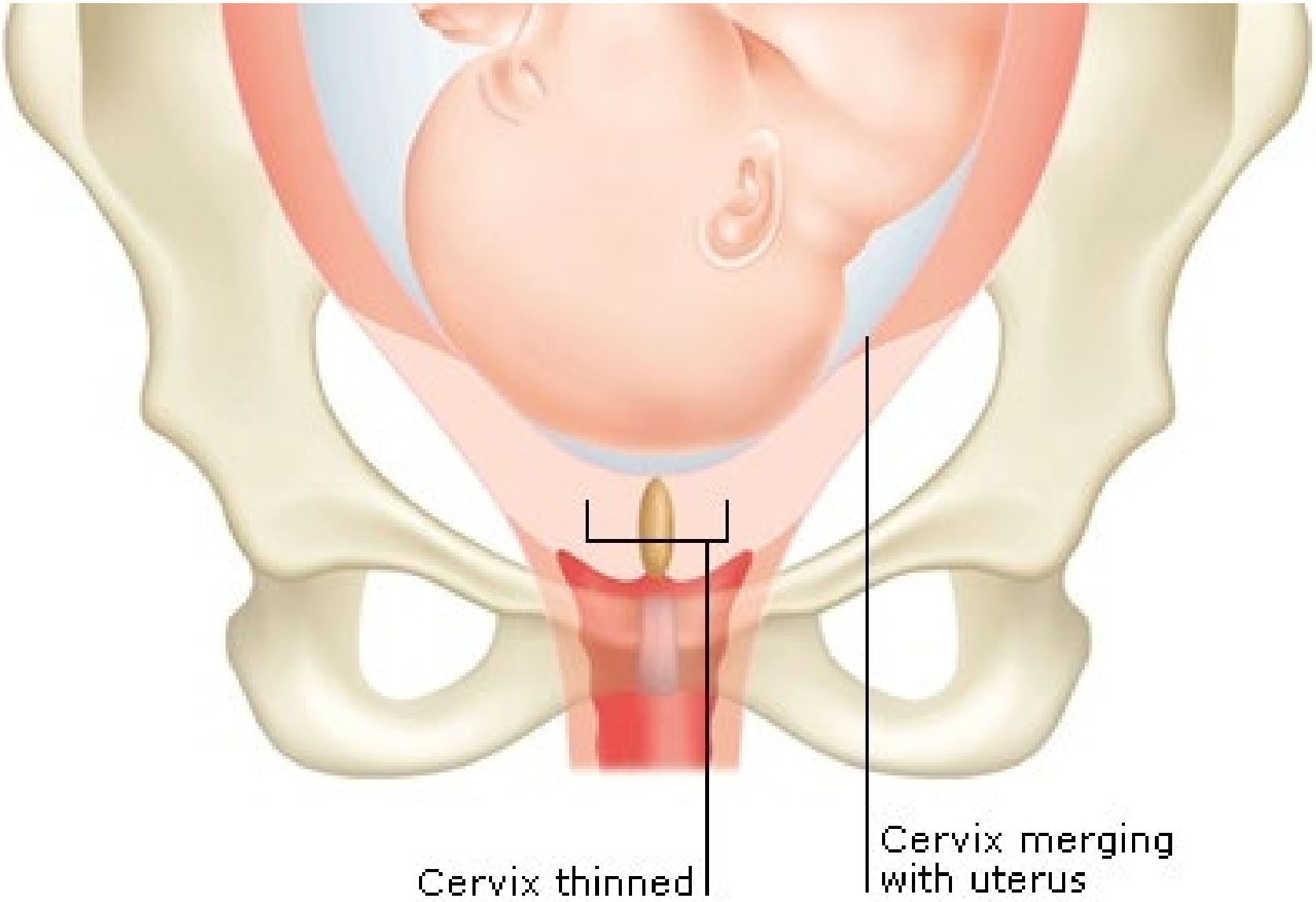

CONTRACTIONS

When pregnancy reaches full-term, the uterus is the largest and strongest muscle in the female body.

When its muscle fibers shorten, with the eventual aim of expelling the fetus, it is known as a uterine contraction or simply a "contraction".

True contractions, as opposed to Braxton–Hicks contractions, are regular and become steadily more frequent, more painful, and longer-lasting.

The main area of contraction is in the uterine fundus (upper uterus), which stretches, causing the lower uterus and cervix to thin.

Judging when true labor has started can be difficult due to "false alarms".

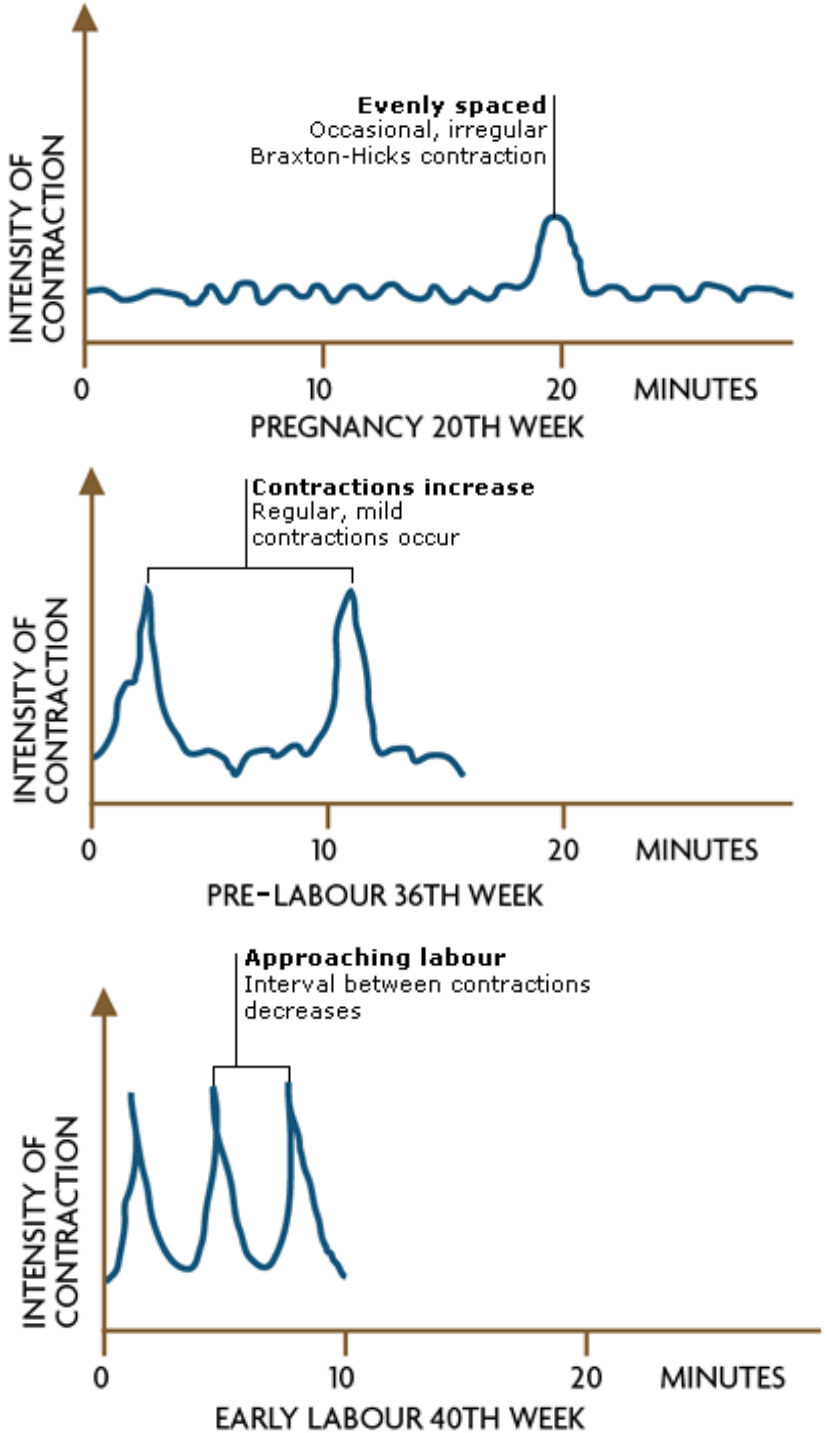

EPIDURAL ANALGESIA

One of the most commonly used methods of pain relief during labor and delivery, epidural analgesia, is delivered via a needle into the space between the vertebrae and the spinal column in the lower (lumbar) region of the back.

It affects the nerve fibers that detect contraction pains.

A new type of epidural, often called a "walking epidural", reduces pain without removing sensation, allowing women to move around during labor and participate actively in the delivery.

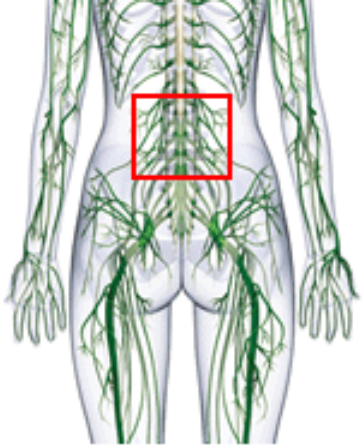

Locator

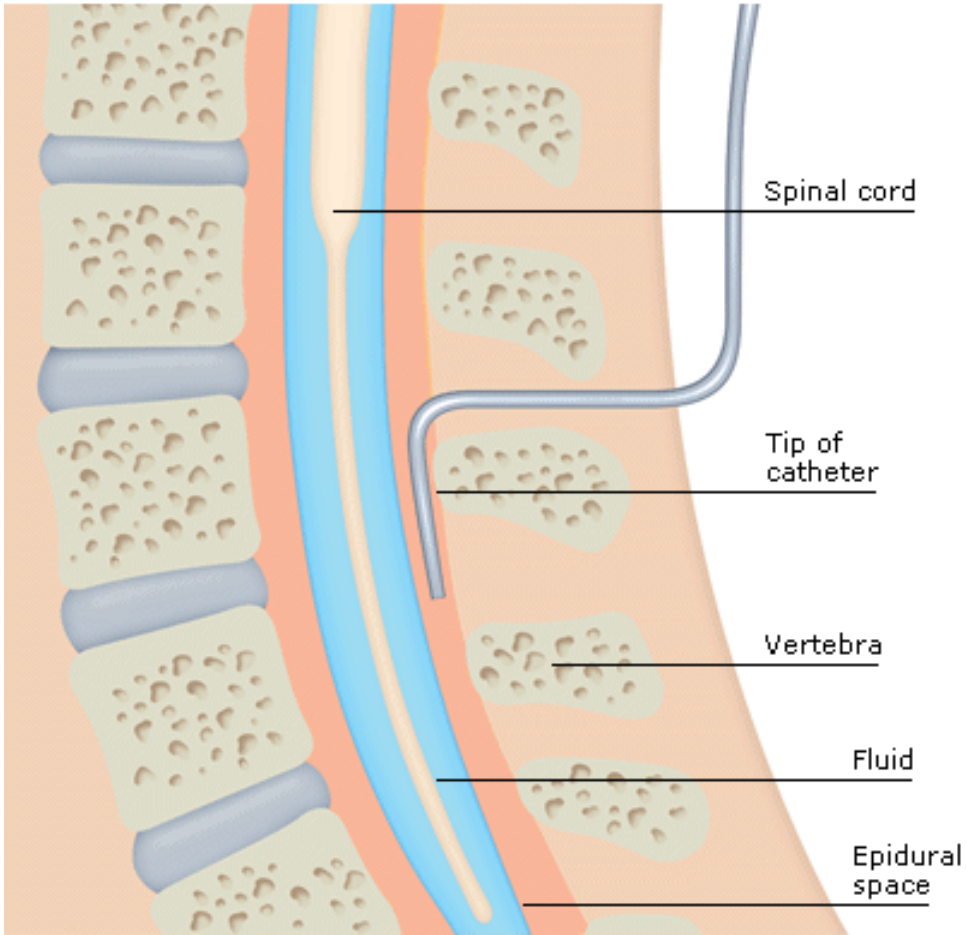

BIRTH OF THE BABY

Around week 36 (usually), the process of labor begins.

In the **first stage**, dilation, hormones stimulate downward contractions of the uterine walls.

The contractions push the head of the fetus against the cervix at the lower end of the uterus.

The cervix dilates.

In the **second stage**, expulsion, powerful contractions push the head and the rest of the body through the dilated cervix, and out through the vagina and the vulva.

The baby is born. Further contractions expel the placenta to complete **the placental stage**.

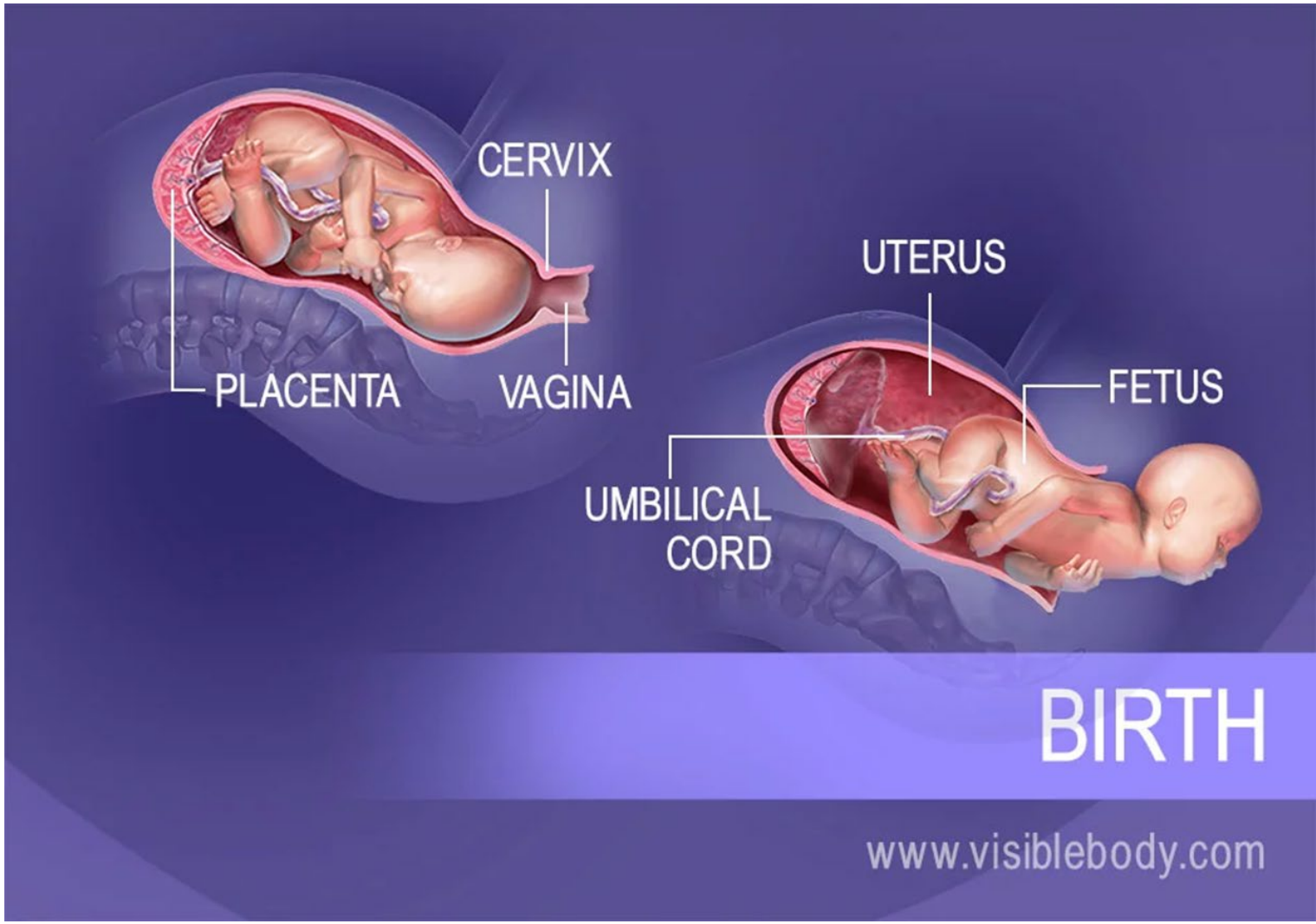

THE END

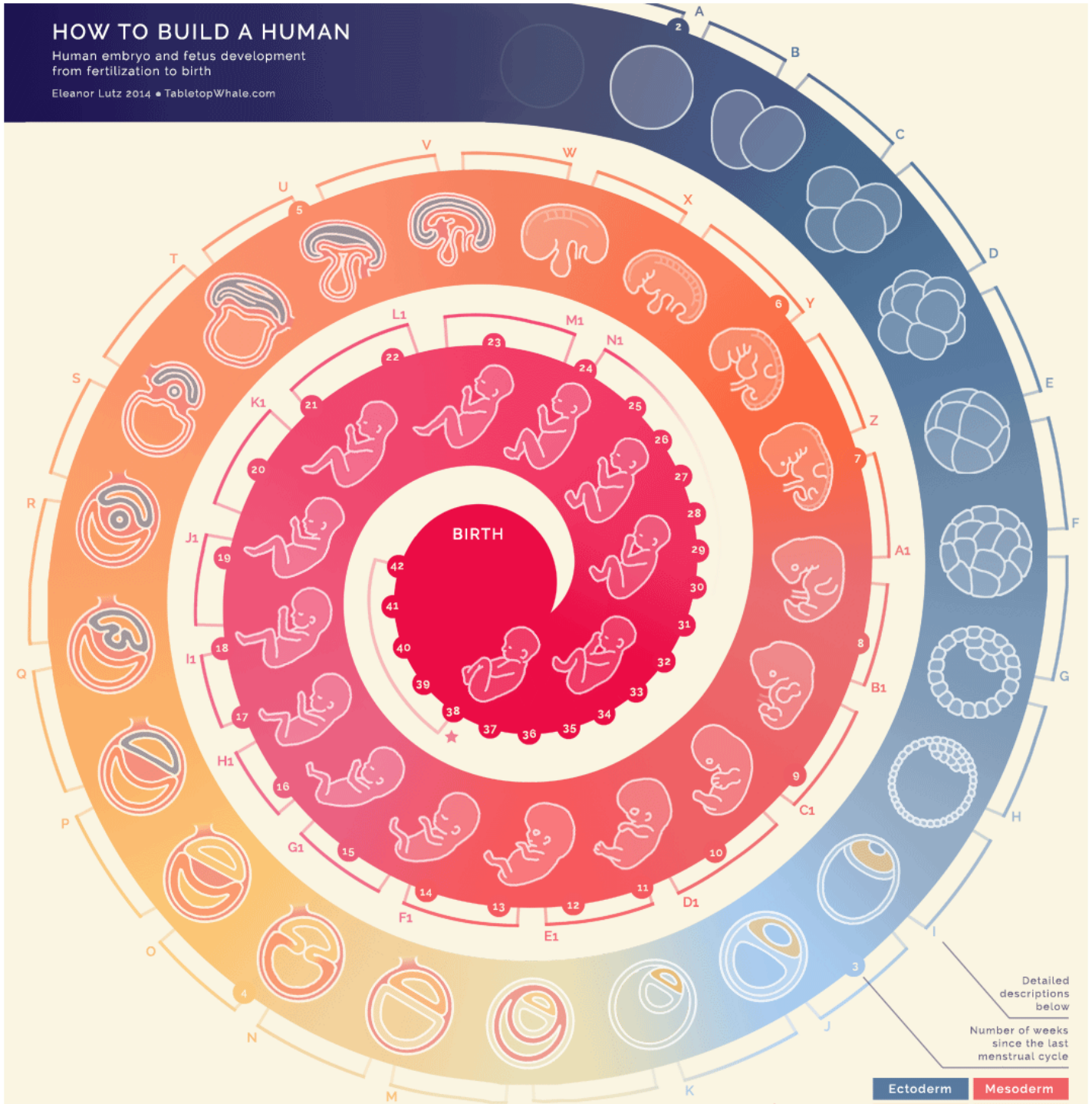
HOW TO BUILD A HUMAN
Human embryo and fetus development from fertilization to birth
Eleanor Lutz 2014 • TabletopWhale.com
BIRTH
Detailed descriptions below
Number of weeks since the last menstrual cycle
Ectoderm
Mesoderm